

SOCIETY OF TRAUMA NURSES

JOINTLY ACCREDITED PROVIDER™
INTERPROFESSIONAL CONTINUING EDUCATION

# THE ELECTRONIC LIBRARY OF TRAUMA LECTURES

In support of improving patient care, MaineHealth is jointly accredited by the Accreditation Council for Continuing Medical Education (ACCME), the Accreditation Council for Pharmacy Education (ACPE), and the American Nurses Credentialing Center (ANCC), to provide continuing education for the healthcare team. MaineHealth is also approved to accredit continuing education activities with the following credit types: Interprofessional Continuing Education (IPCE), Association of Social Work Boards (ASWB), American Academy of Physician Assistants (AAPA), American Psychological Association (APA), Registered Dietitians (RDs) and Dietetic Technicians, Registered (DTRs).

THE ELECTRONIC LIBRARY OF

TRAUMA LECTURES

# Maxillofacial and Ocular Injuries

SOCIETY OF TRAUMA NURSES

# Objectives

**At the conclusion of this presentation the participant will be able to:**

- Identify the key anatomical structures of the face and eye and the impact of force on those structures.
- Discuss assessment priorities for a patient with maxillofacial and ocular injuries.
- Prioritize the care of a patient with facial and ocular injuries.
- Discuss psychosocial support for a patient with maxillofacial and ocular injuries.

# Mechanism of Injury

Low velocity

High velocity



# Pathophysiology

- Bones of face make up the most complex skeletal area of the body.
- Maxillofacial fractures result from either blunt or penetrating trauma.

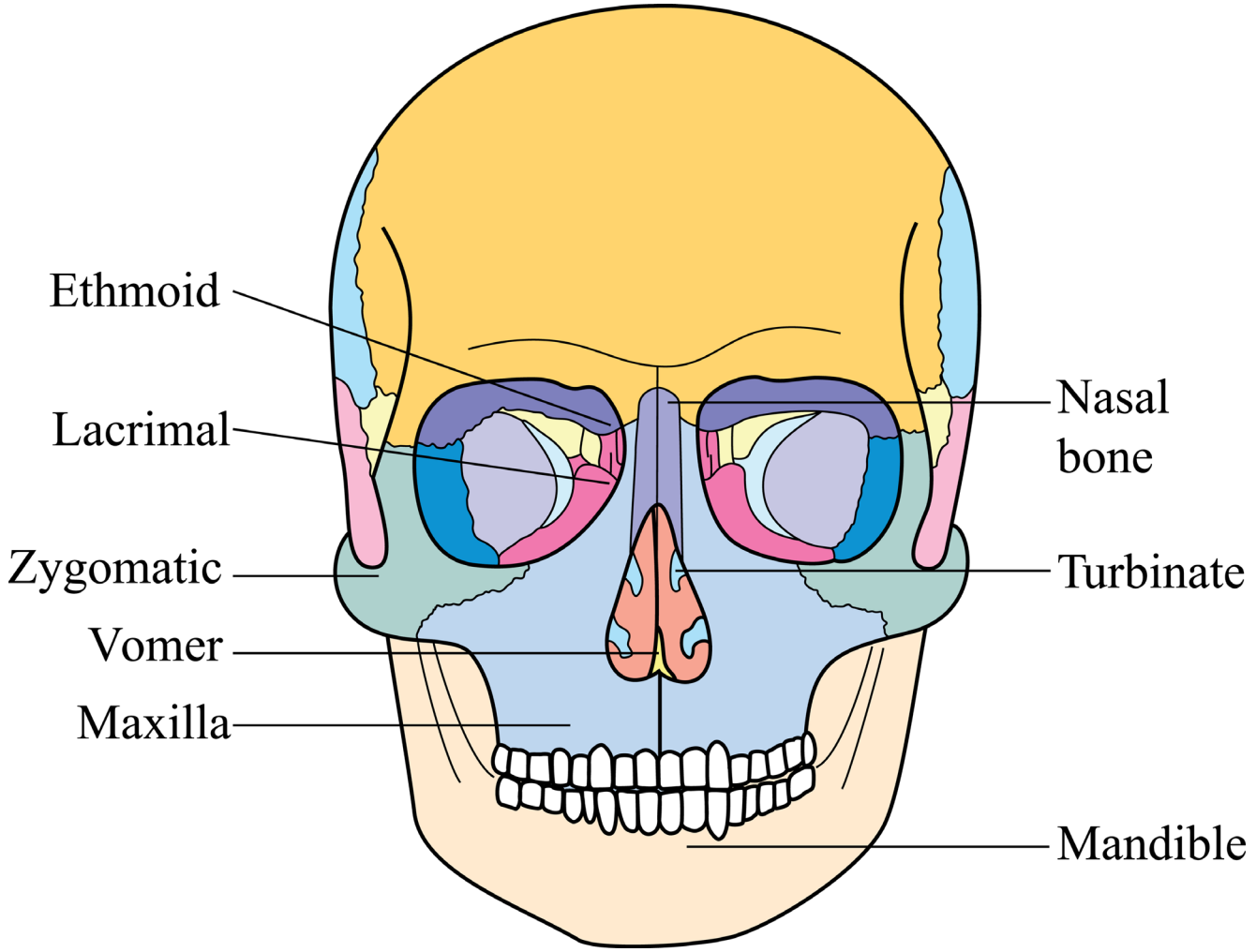

# Pathophysiology

- ‘G’ force is a measure of acceleration not produced by gravity
- **High Impact:**
  - Supraorbital rim – 200 G
  - Symphysis Mandible –100 G
  - Frontal – 100 G
  - Angle mandible – 70 G
- **Low Impact:**
  - Zygoma – 50 G
  - Nasal bone – 30 G

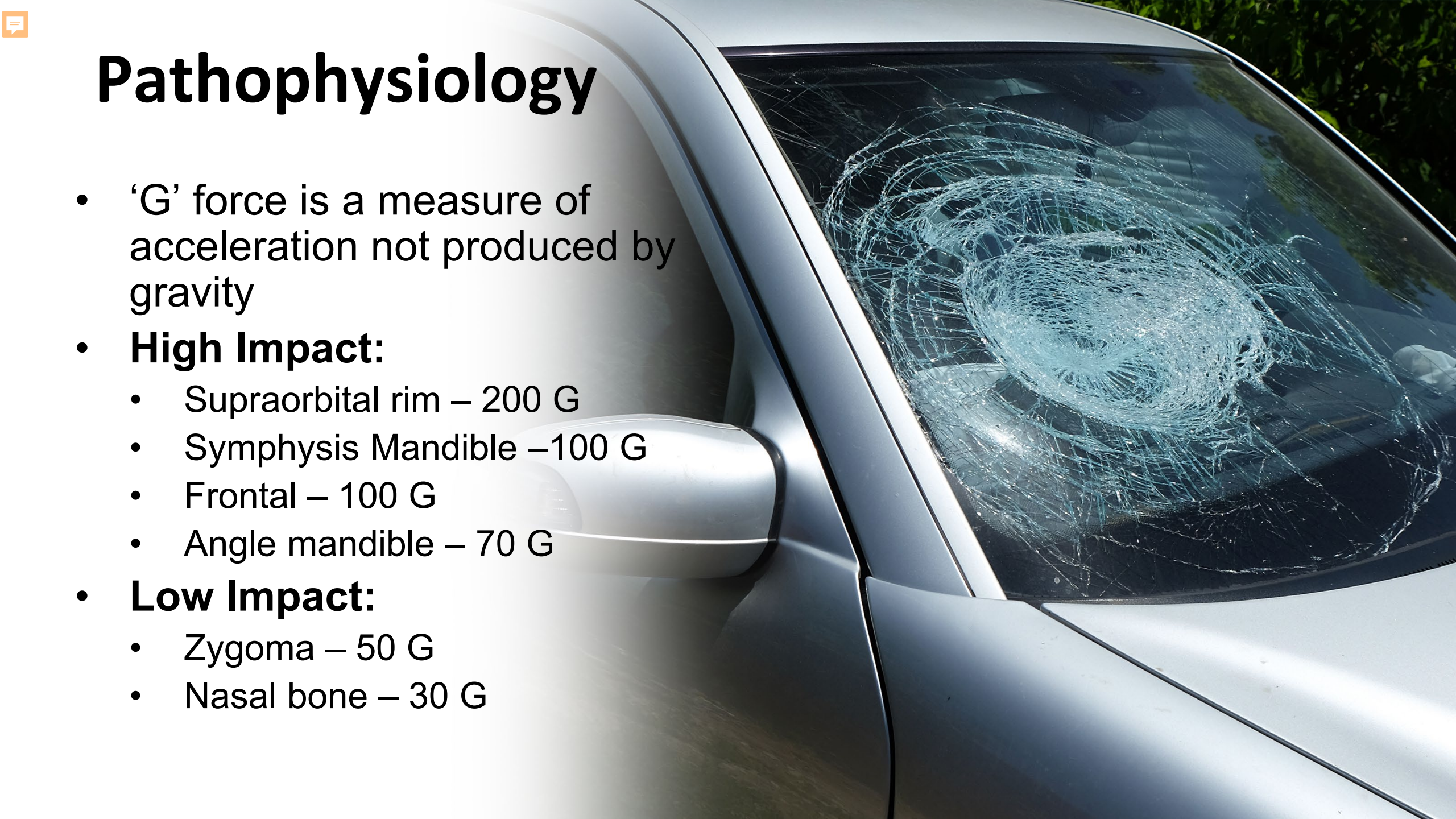

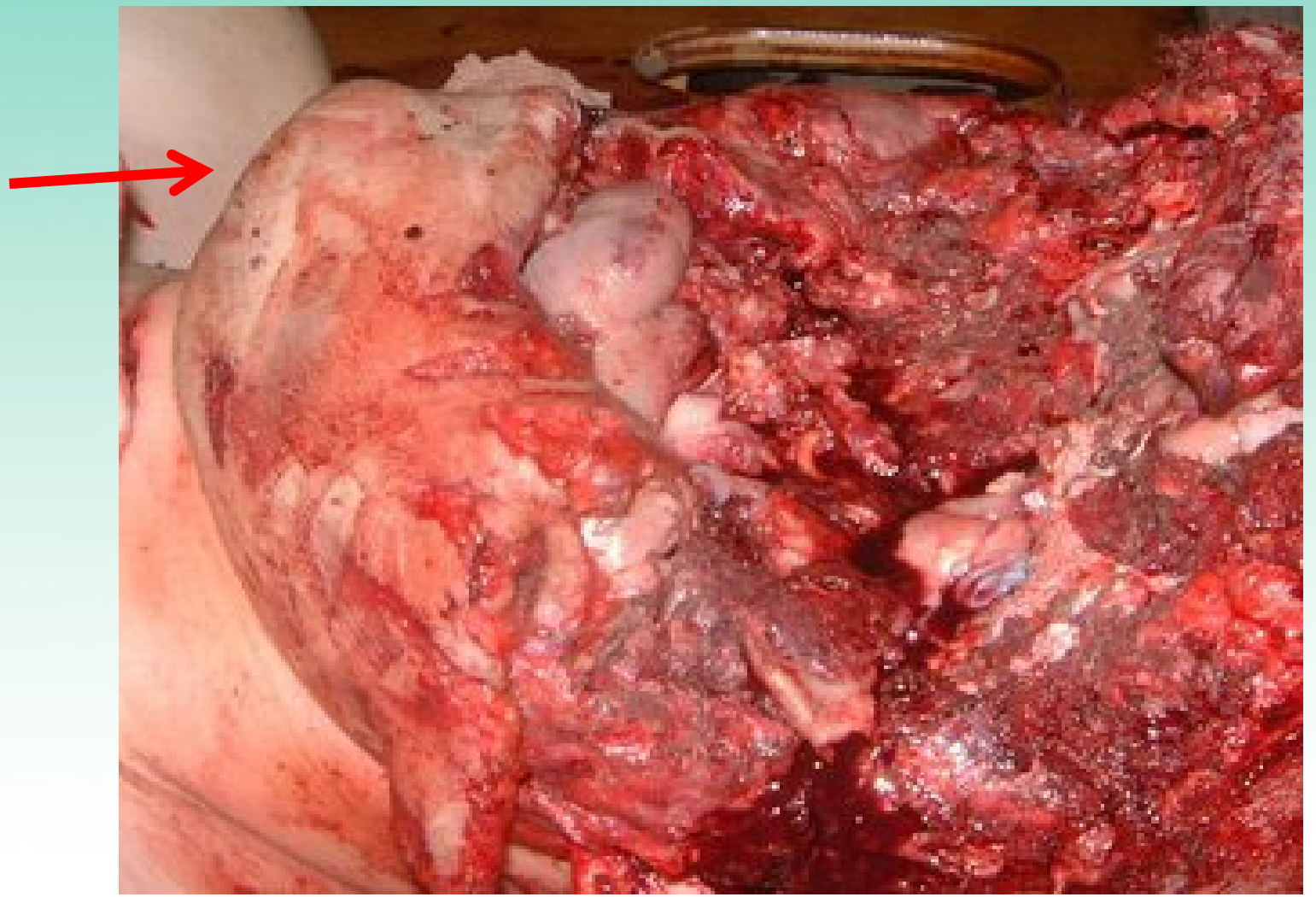

# Etiology

60% of patients with severe facial trauma have multisystem trauma and the potential for airway compromise.





# Etiology

- Approximately one quarter of women with facial trauma are victims of domestic violence.
  - Index of suspicion increases if an orbital wall fx is present.
- Approximately one quarter of patients with severe facial trauma will develop Post Traumatic Stress Disorder.

# Ocular Structures

## Human Eye Anatomy

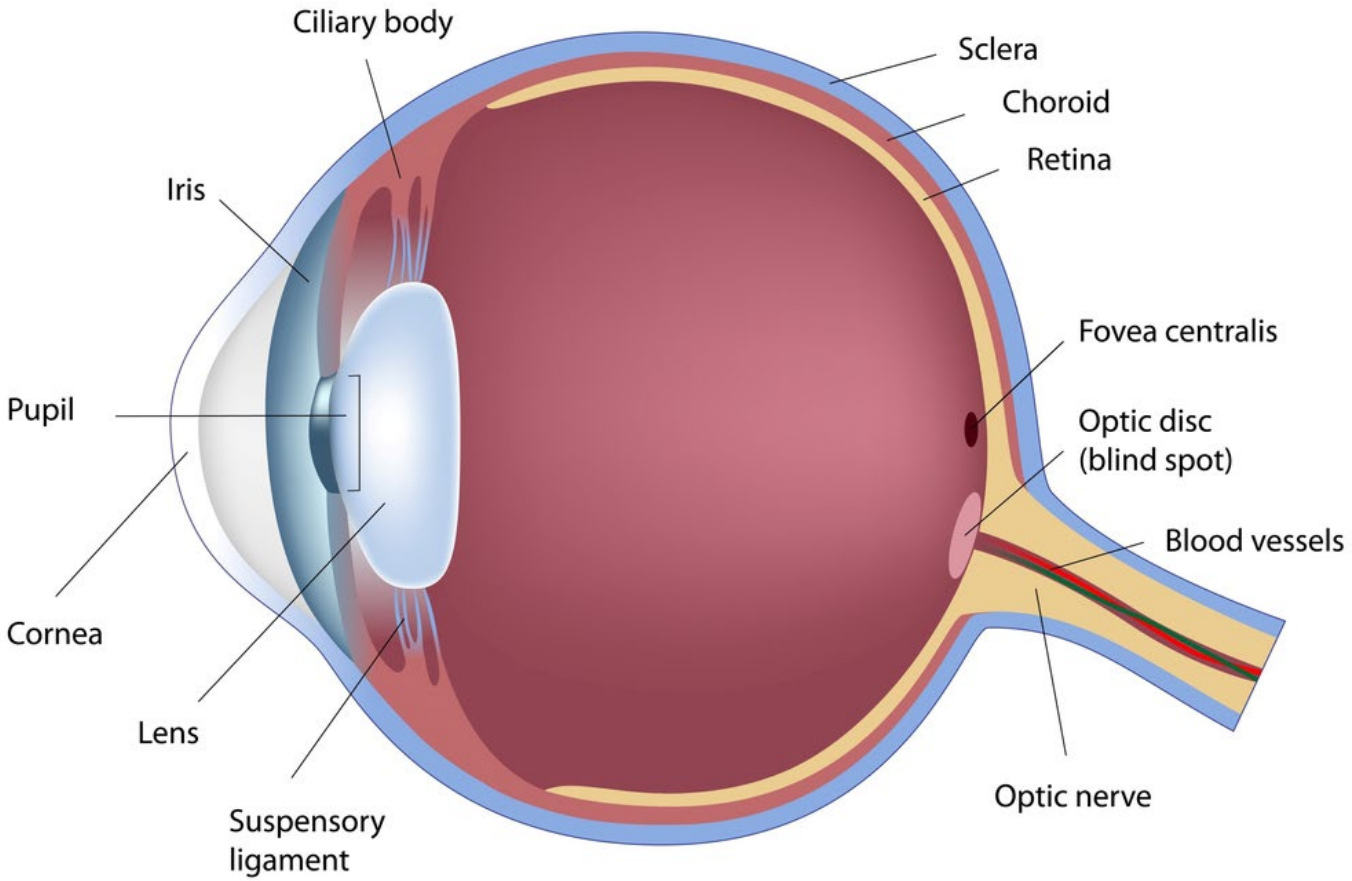

# Bony Orbit

- Roof
  - Frontal bone
  - Sphenoid
- Medial wall
  - Maxilla
  - Lacrimal, ethmoid
  - Body of sphenoid
- Floor
  - Maxilla
  - Palatine
  - Zygoma
- Lateral
  - Zygoma and greater sphenoid

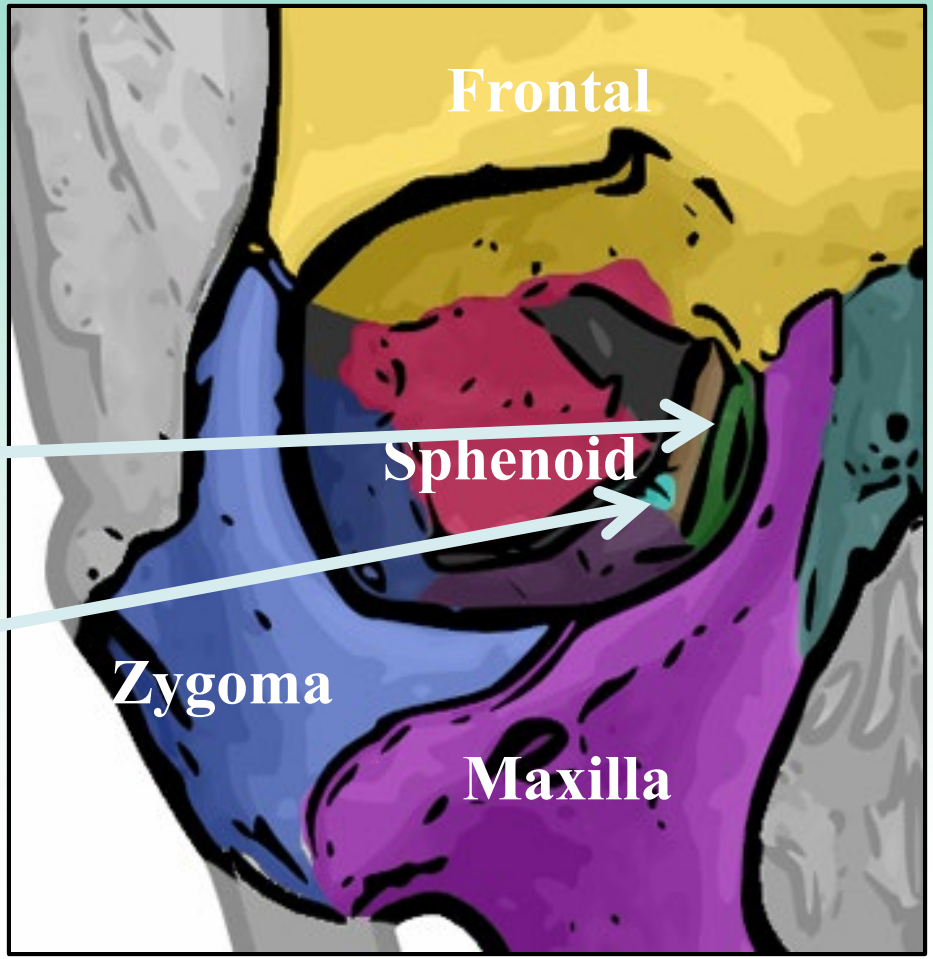


Je at uwo at English Wikipedia., CC BY 2.5, via Wikimedia Commons

# Cranial Nerves

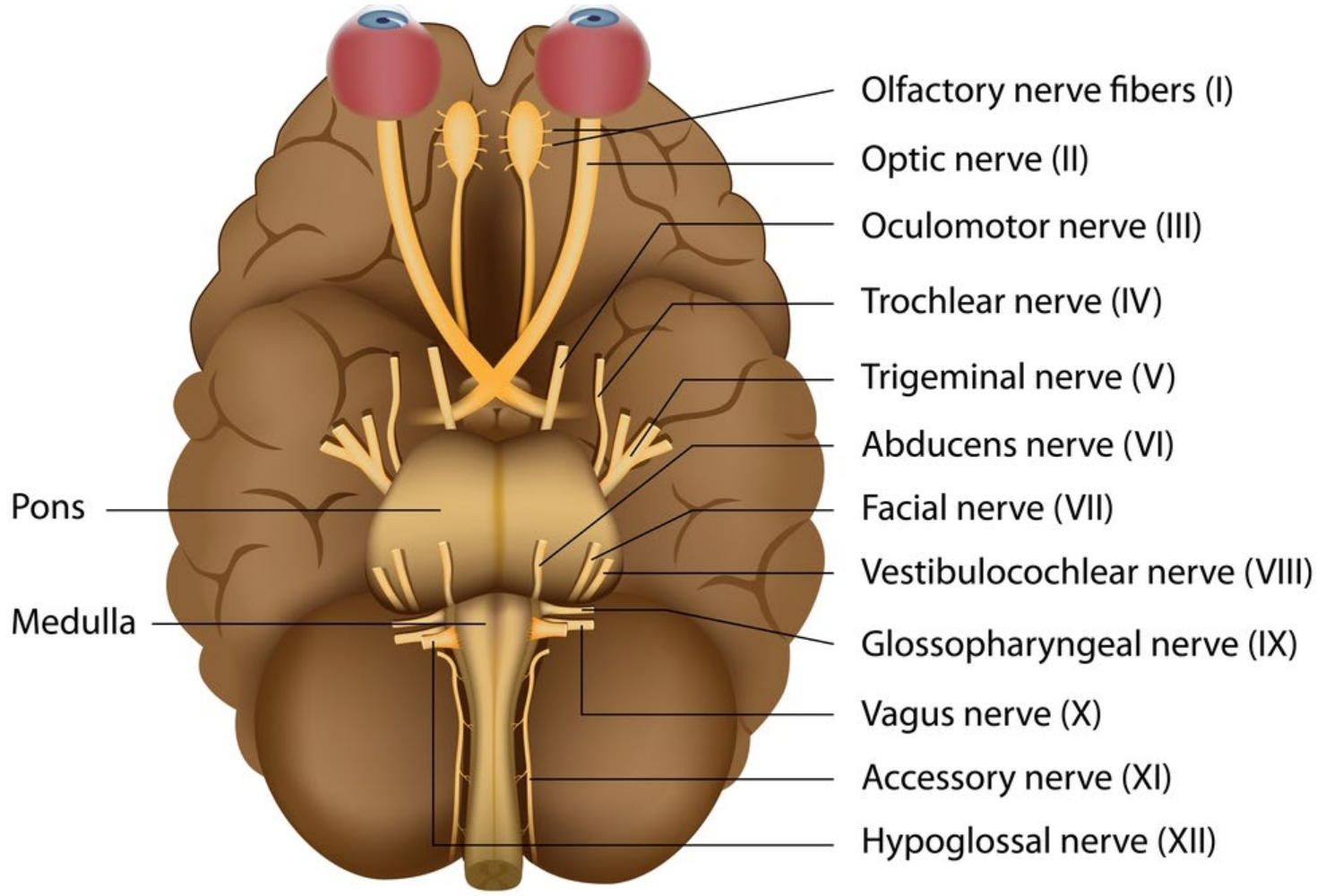

# Orbital Fractures

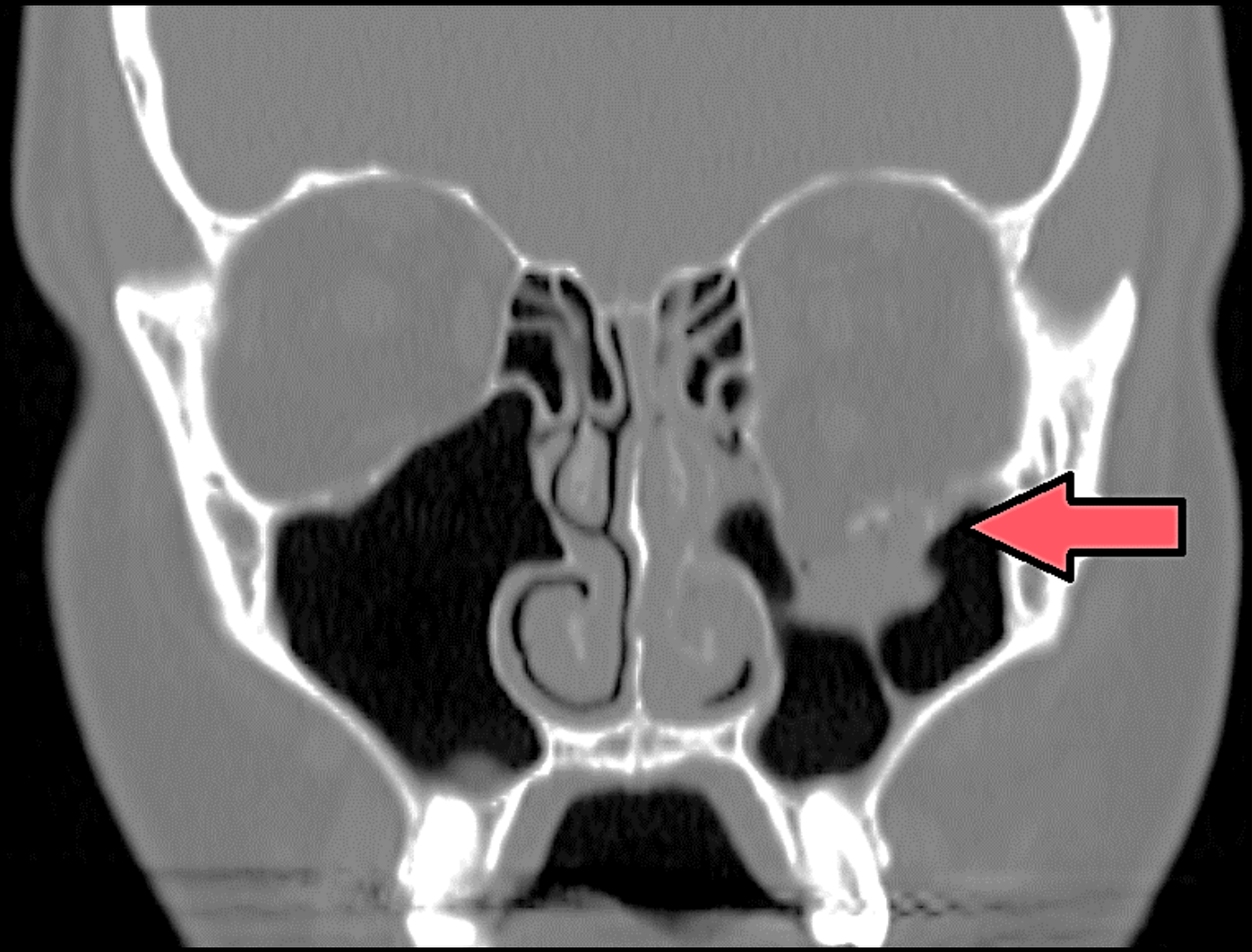

James Heilman, MD, CC BY-SA 4.0, via Wikimedia Commons

# Orbital Fractures

- Usually through floor or medial wall
- Enophthalmos
- Anesthesia
- Diplopia
- Infraorbital stepoff deformity
- Subcutaneous emphysema

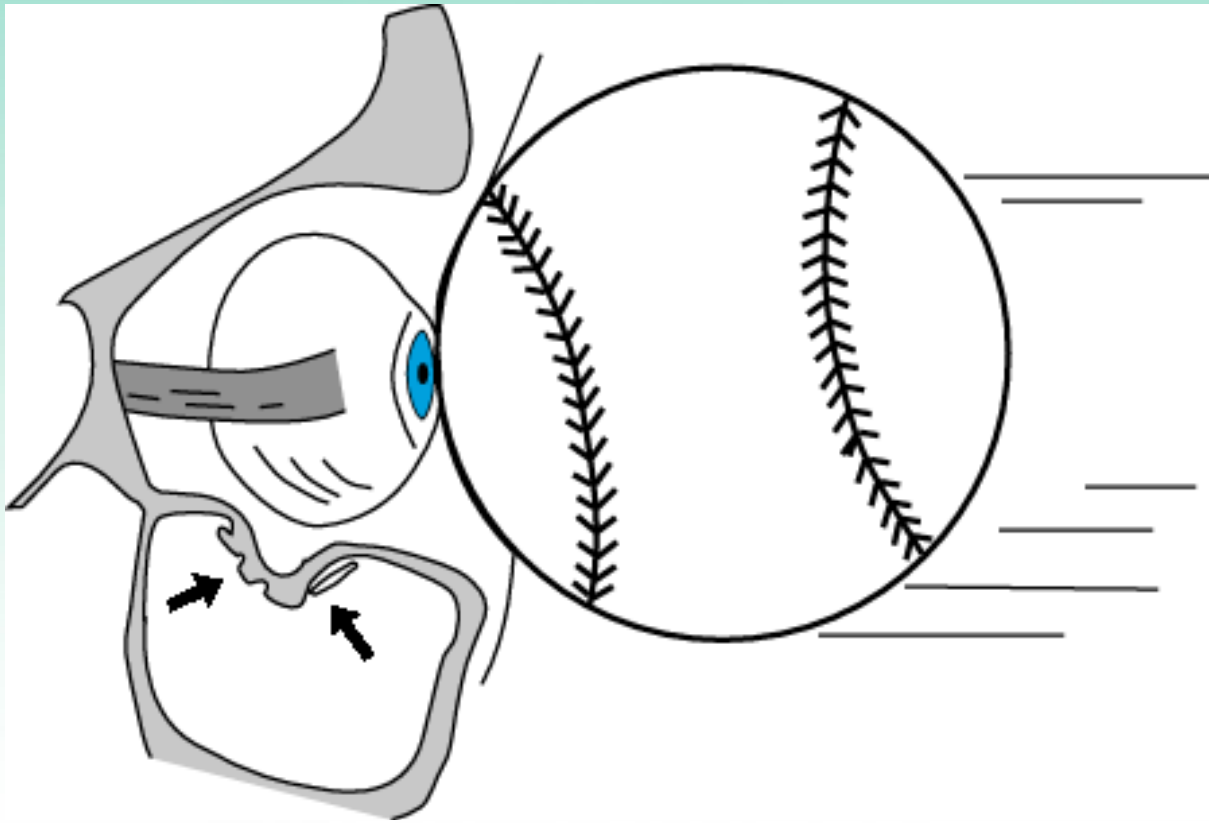

Lipa, et al. (2015)

# Orbital Fractures

- Symptoms
  - Periorbital swelling
  - Crepitus
  - Proptosis
  - Ophthalmoplegia
  - Enophthalmos
  - Palpable defects
- Assess for globe injury
- Avoid nose blowing
- Assess for entrapment

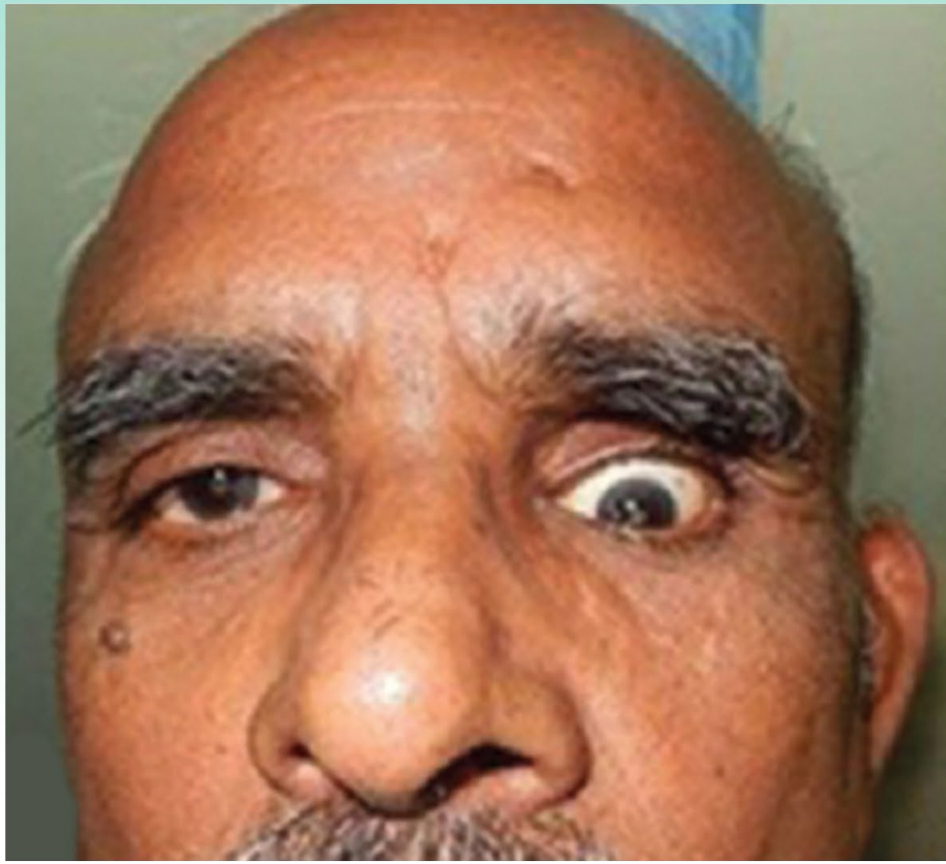

Jha, 2018



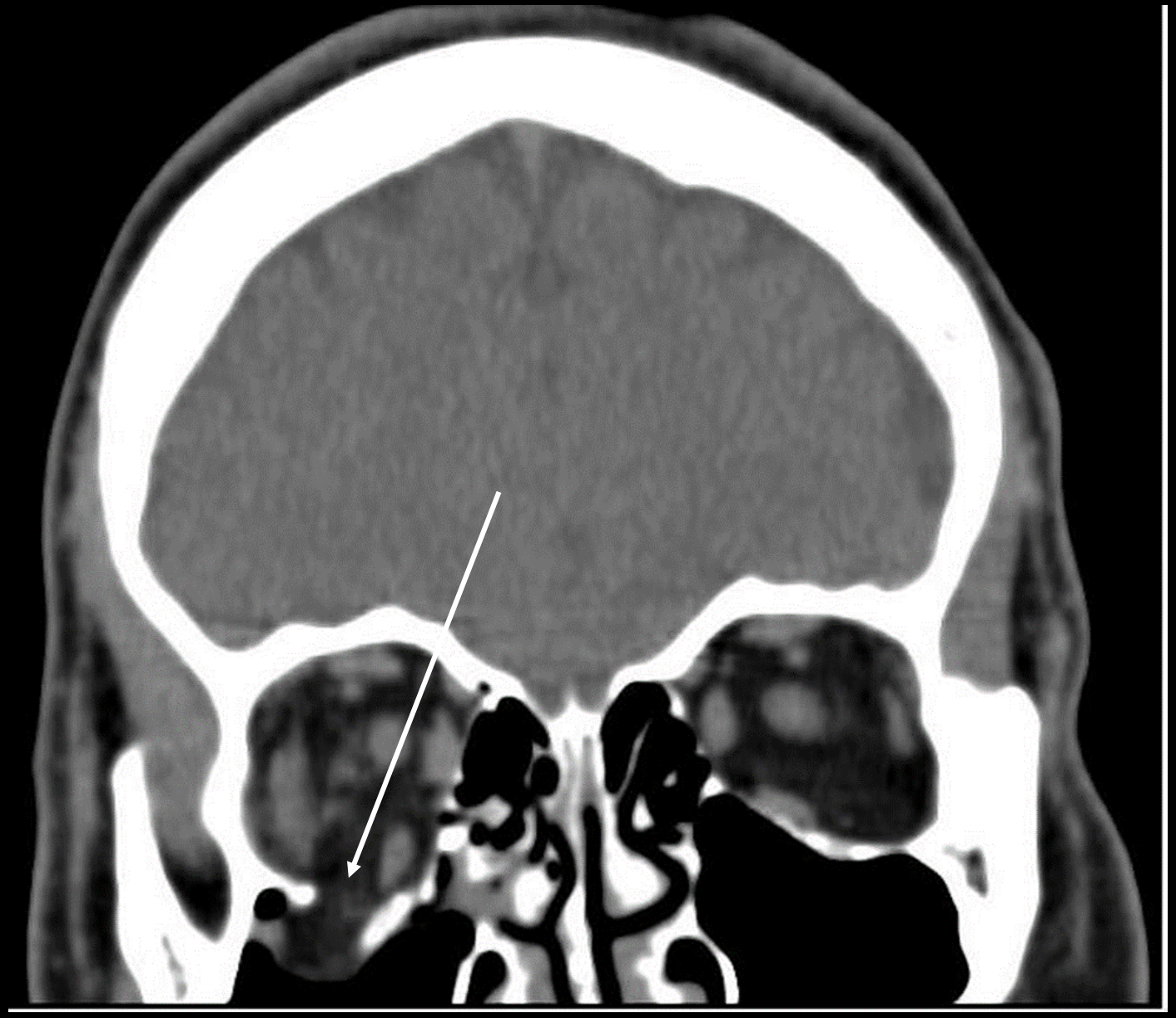

Gaillard, Radiopedia.org

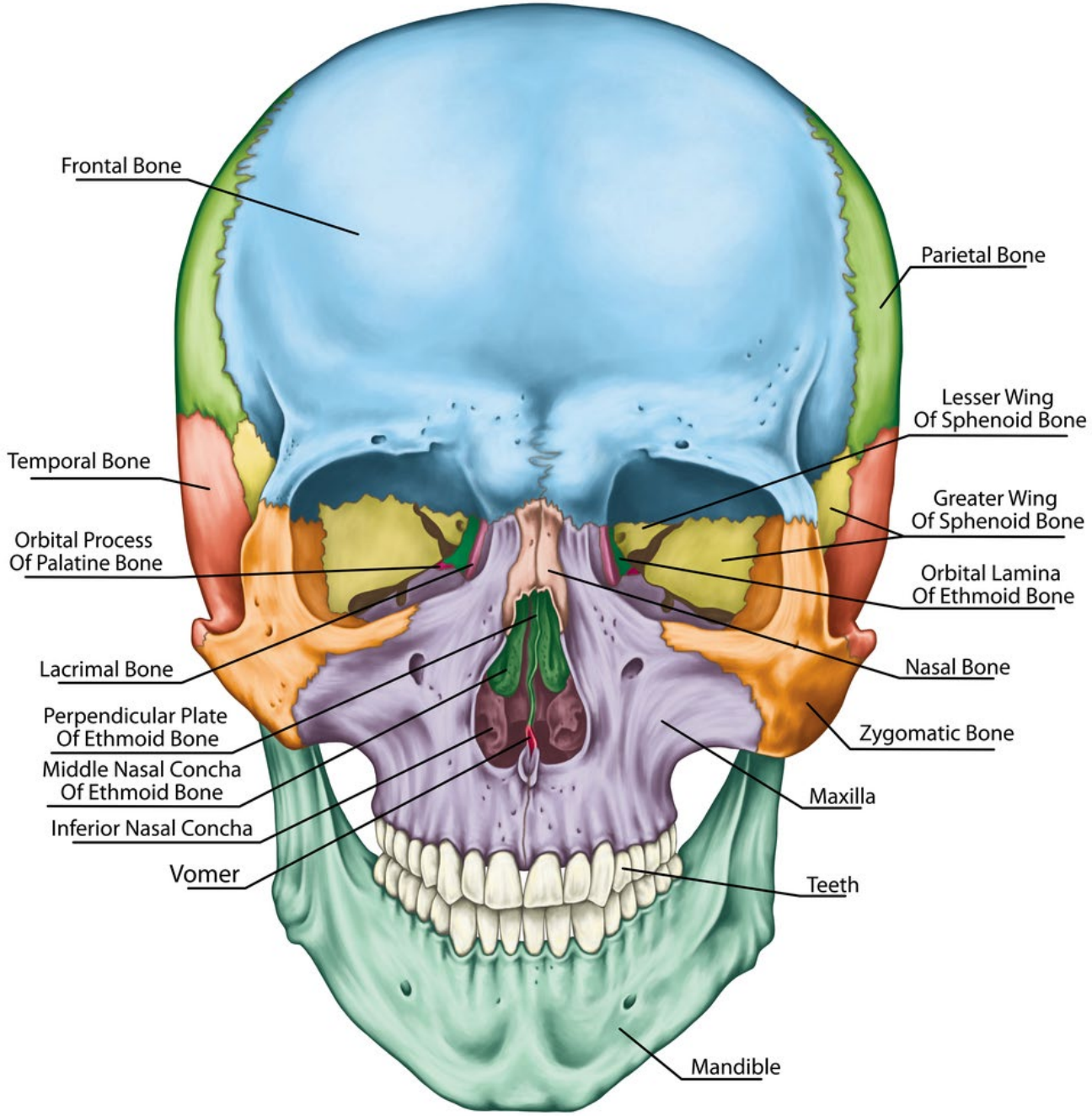


# Facial Structures

# LeFort I Fracture

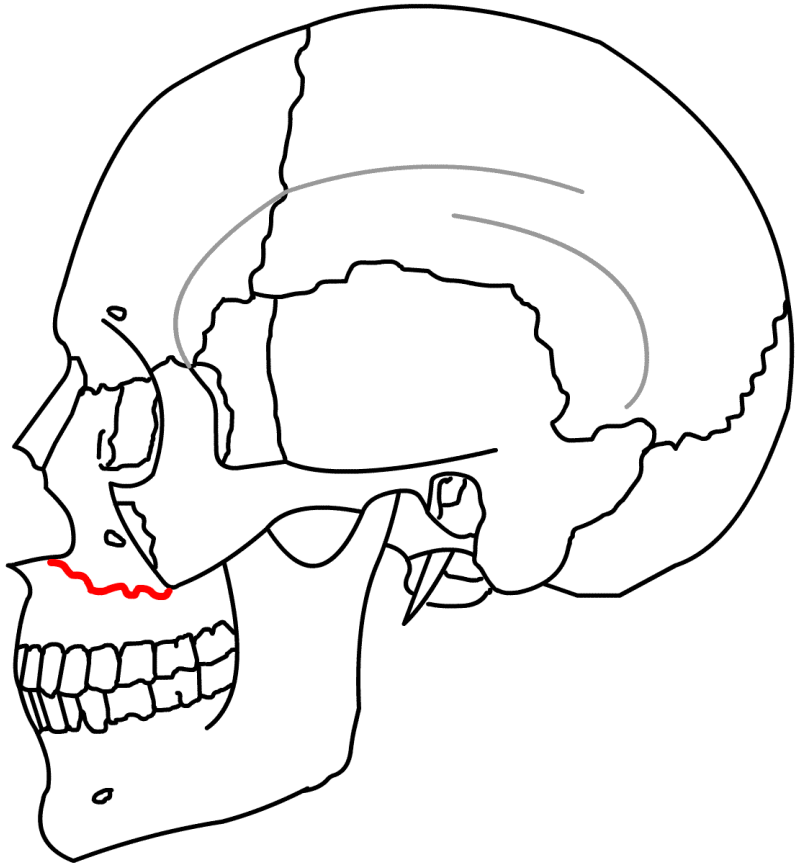

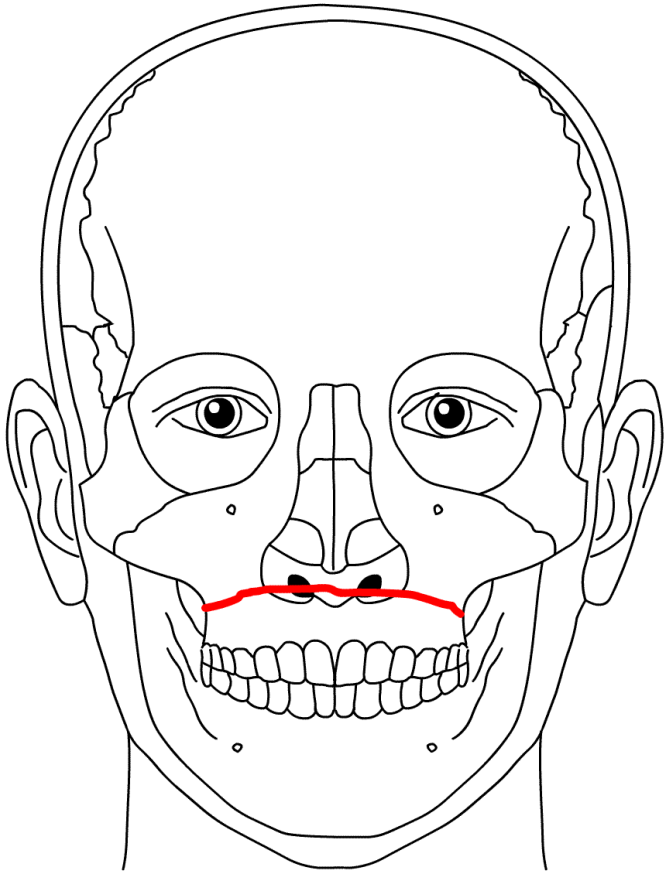

I, RosarioVanTulpe, CC BY-SA 3.0, via Wikimedia Commons

# LeFort II Fracture

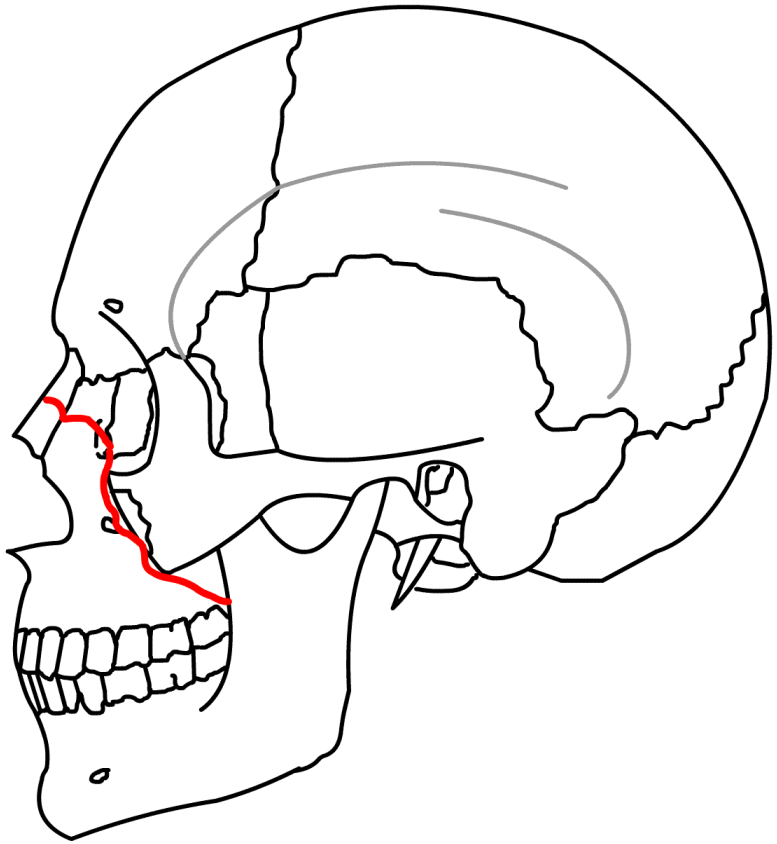

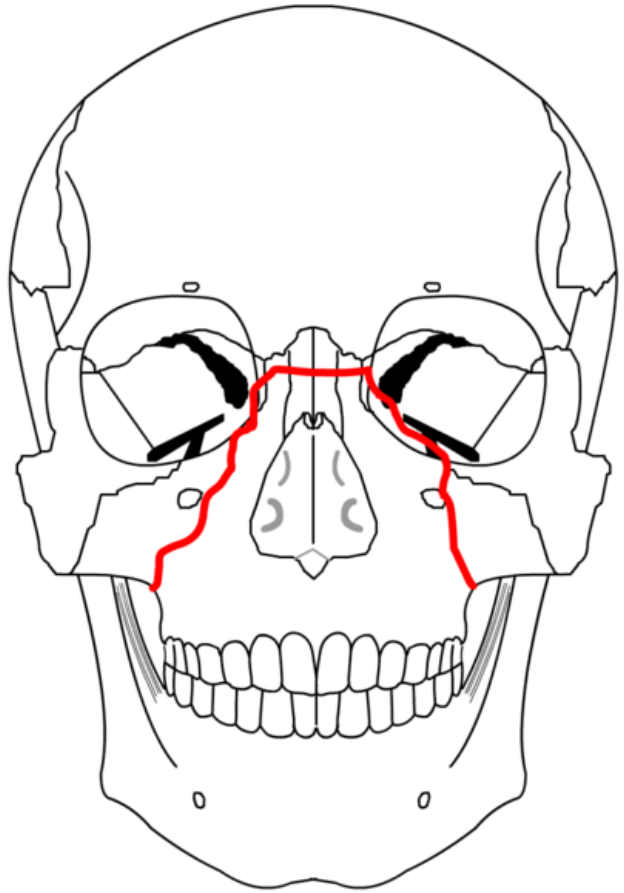

I, RosarioVanTulpe, CC BY-SA 3.0, via Wikimedia Commons

# LeFort III Fracture

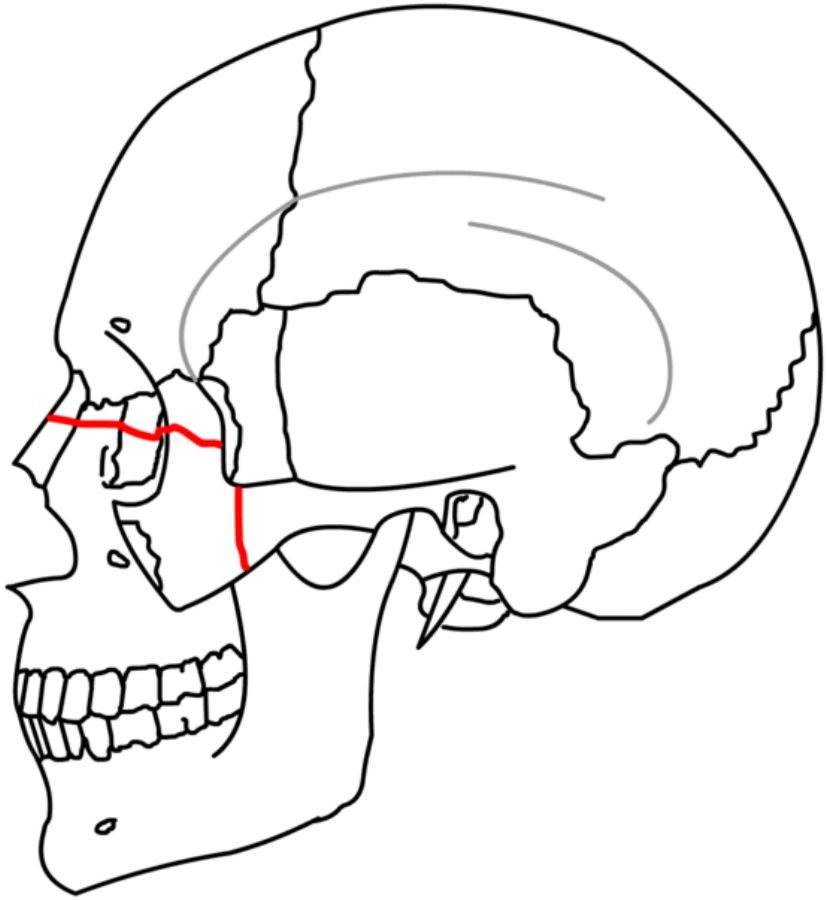

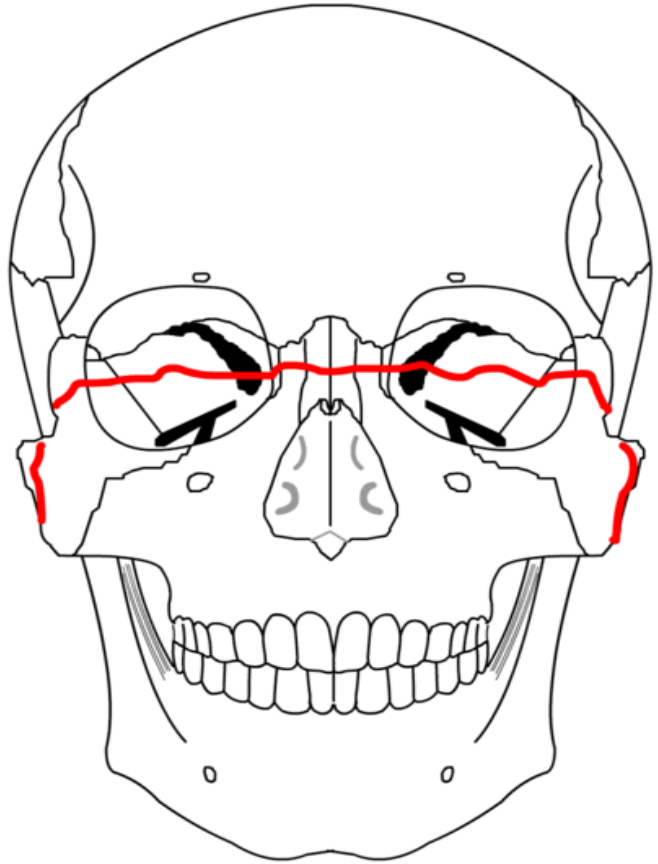

I, RosarioVanTulpe, CC BY-SA 3.0, via Wikimedia Commons

# Le Fort III Fracture

- Periorbital hematoma
- Racoon eyes suggestive of basal skull fracture.
- Inappropriate placement of nasogastric tube.



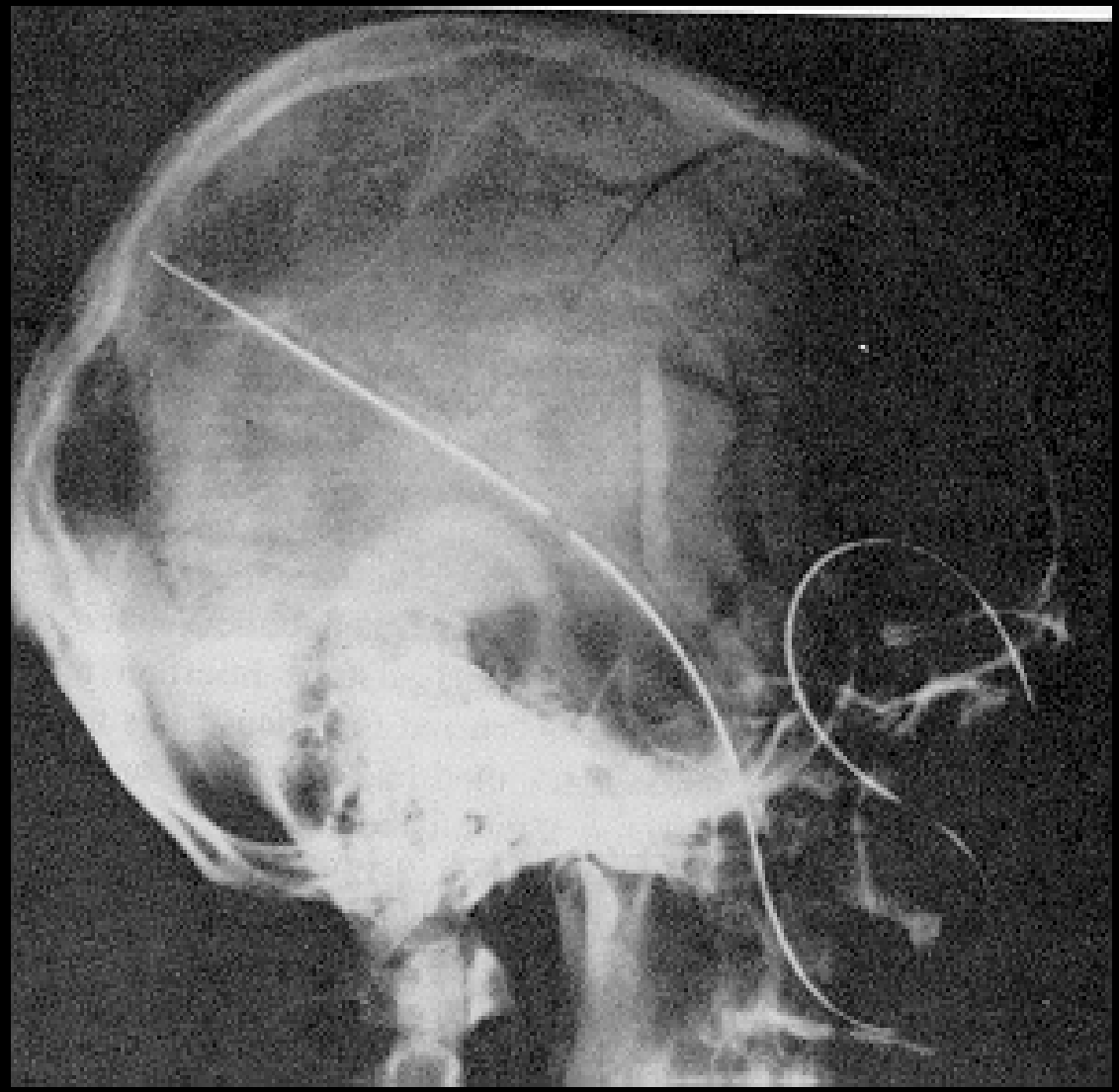

# Tripod Fracture

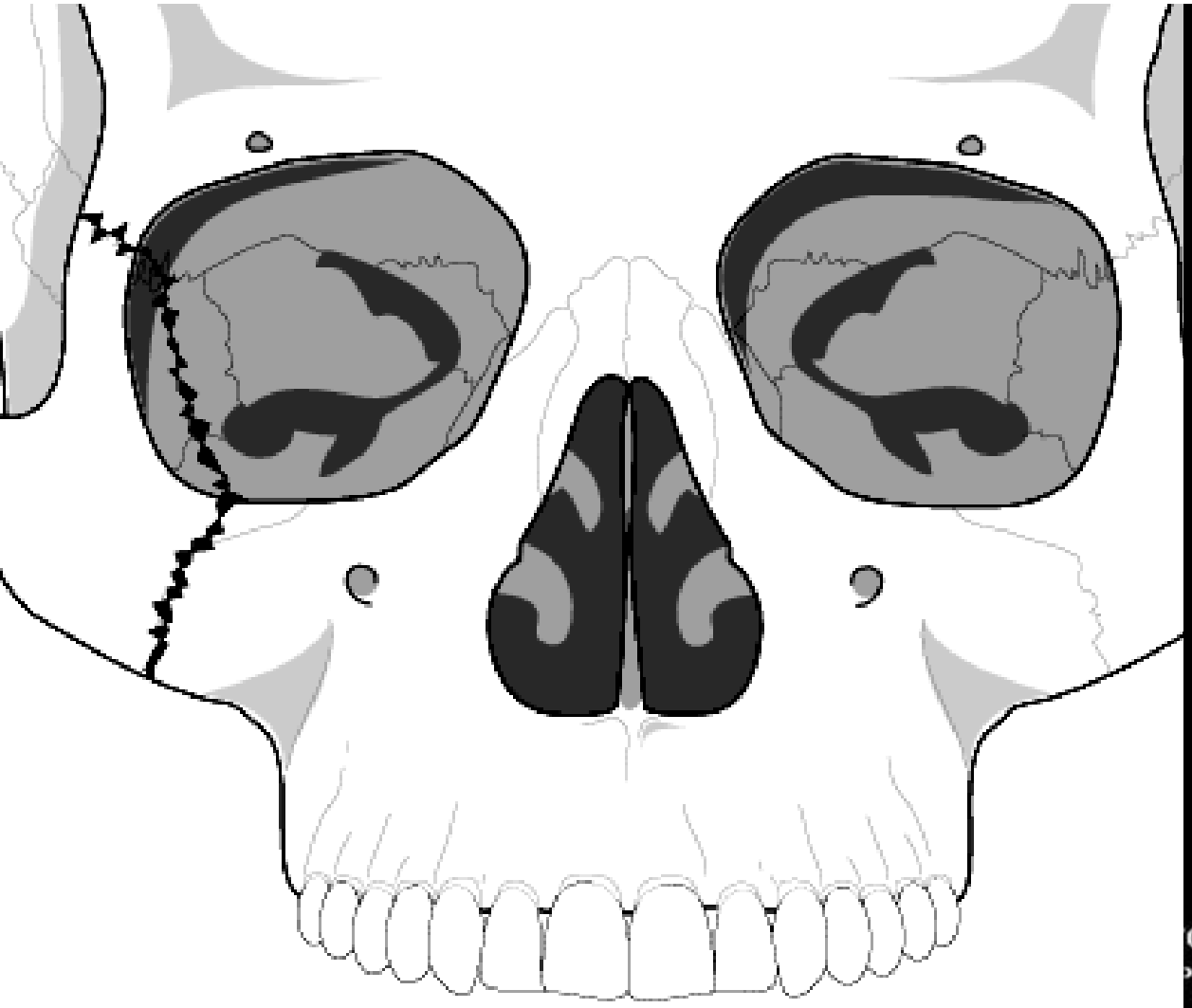

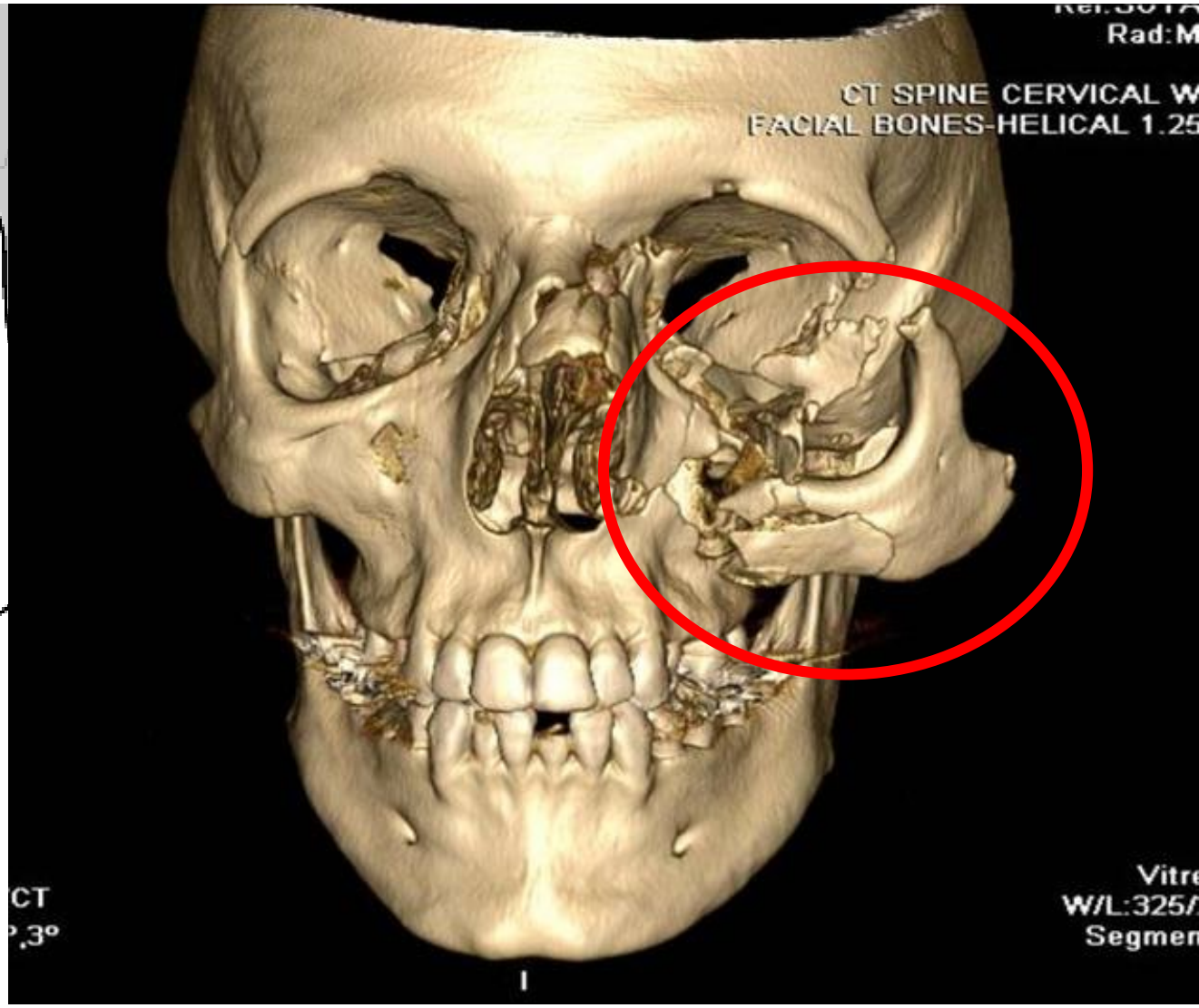


https://thetraumapro.com/2013/11/19/the-tripod-fracture/

Siddiqui, Radiopaedia.org

# Orbitozygomatic Fractures



- Complex fractures of the zygoma and orbital floor.
- May have double vision, ocular proptosis or enophthalmos.
- Must assess for entrapment of extraocular muscles.
- Surgical management directed at decompression of entrapped muscles and anatomic realignment of zygoma.

I enjoy sandwiches, CC BY-SA 4.0 via Wikimedia Commons

# Naso-Ethmoidal-Orbital Fracture

- Fractures that extend into the nose through the ethmoid bones.
- Associated with lacrimal disruption and dural tears.
- Suspect if there is trauma to the nose or medial orbit.
- Patients complain of pain on eye movement.

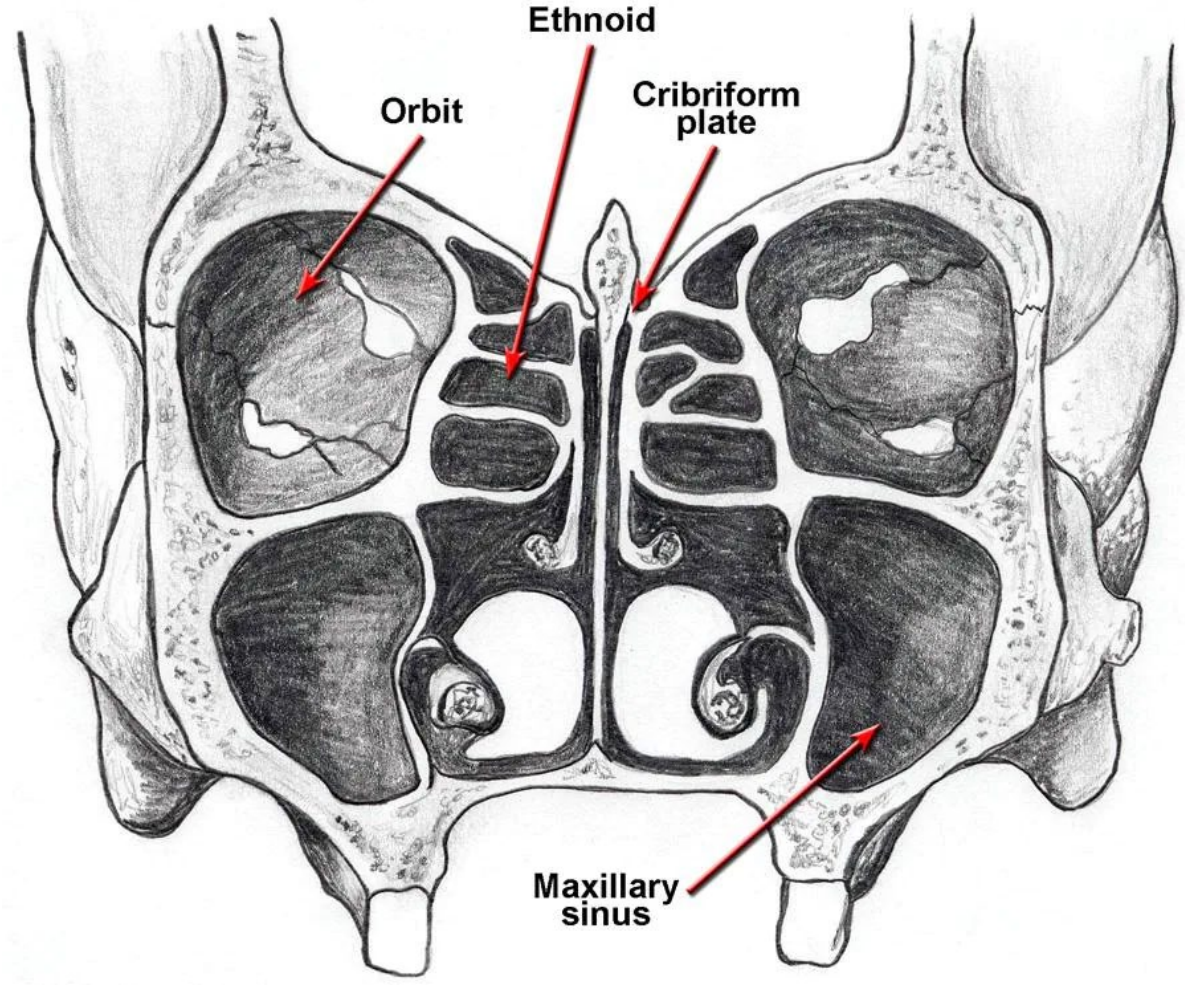


Tollefson, 2021

# Mandibular Fractures

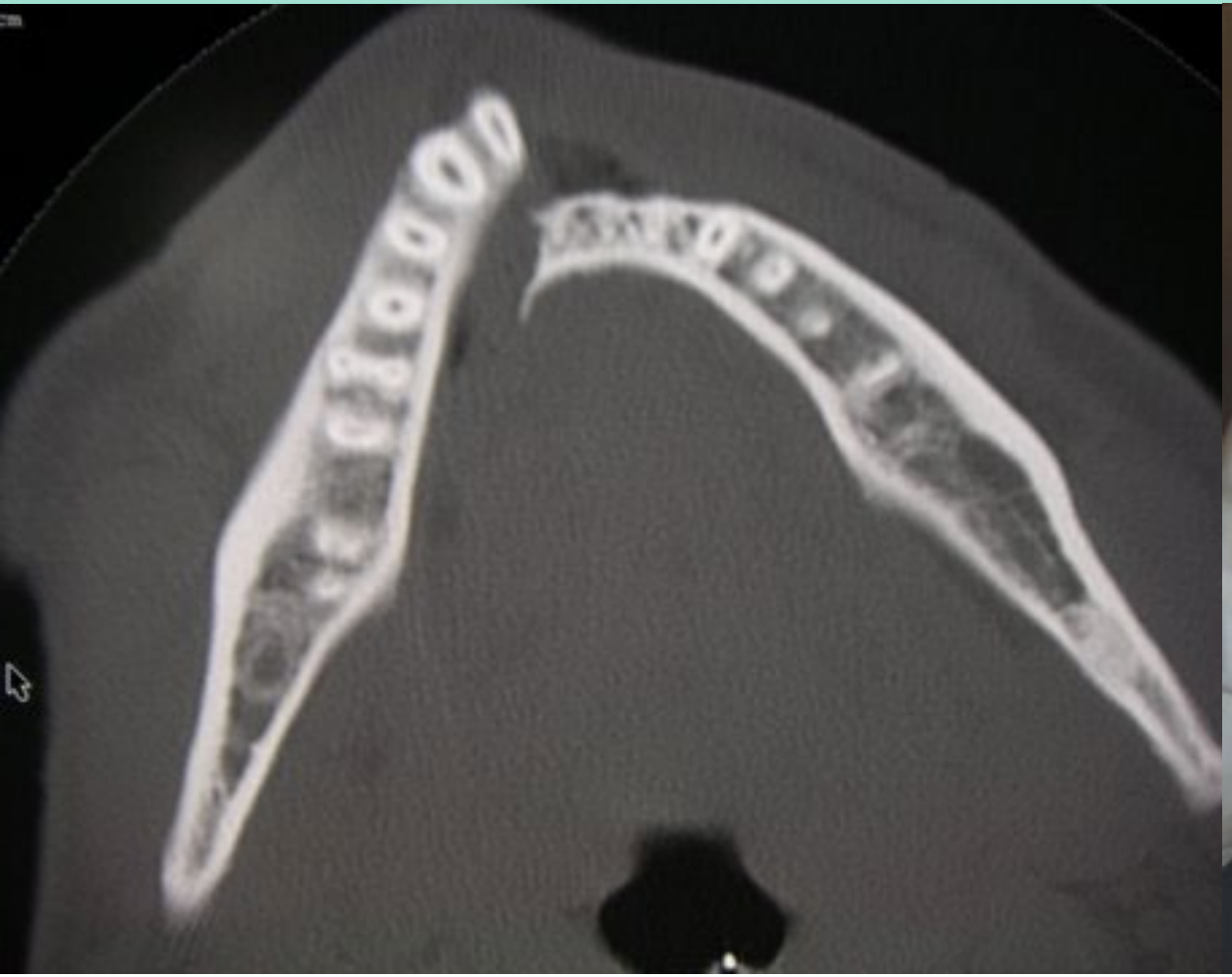





# Mandible Fractures

- Pain
- Malocclusion
- Separation
- Inability to open mouth
- Tongue blade test

# Tongue Blade Test

- Screening test
- Have patient bite tongue blade
- Rotate blade laterally
- 96% sensitive for mandibular fx



Peterson, 2014

# Treatment

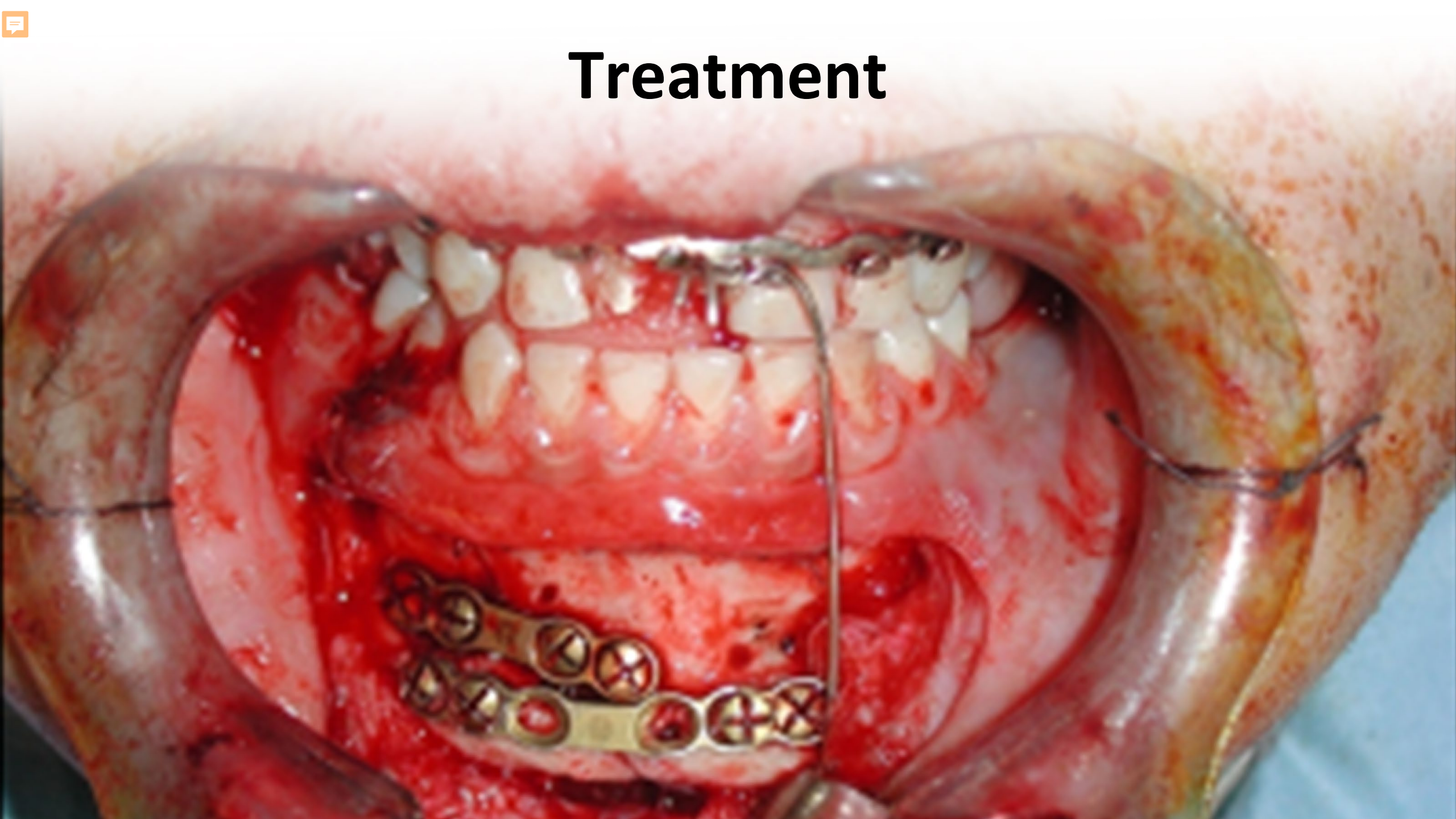

# Maxillofacial Injuries General Assessment




- ABC's
- Assess for symmetry of facial structures
  - Assess for paresthesias
  - Assess symmetry of facial movements
- Assess the ears, nose and oral cavity for occult lacerations, hematomas
- Palpate for crepitus, tenderness or deformity
- Assess sense of smell

# Ocular Assessment

- Visual acuity
- Pupil assessment
- Extraocular movements
- Eye position and movement
- Intraocular pressure



# Physical Examination

- Inspect open wounds for foreign bodies.
- Palpate the entire face.
- Inspect the nose.
- Inspect nasal septum for septal hematoma, CSF or blood.
- Palpate nose for crepitus, deformity and subcutaneous air.
- Palpate the zygoma along its arch and its articulations with the maxilla, frontal and temporal bone.

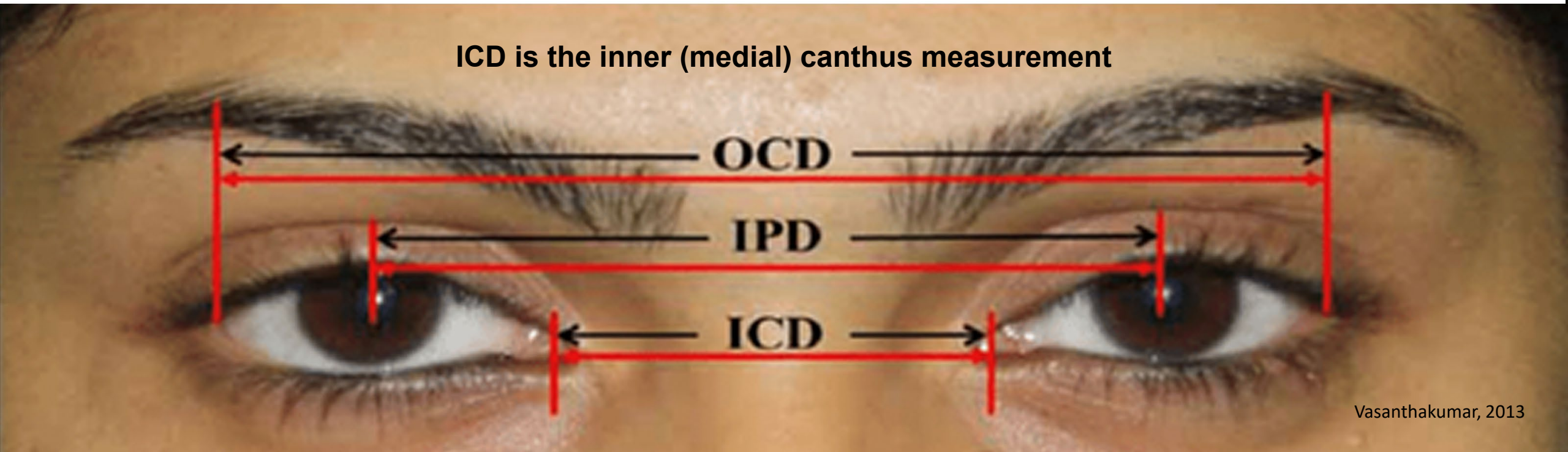

# Physical Examination

- Inspect the teeth
- Intraoral examination:
  - Check for lacerations
  - Stress the mandible
  - Tongue blade test
- Palpate the mandible for tenderness, swelling and step-off

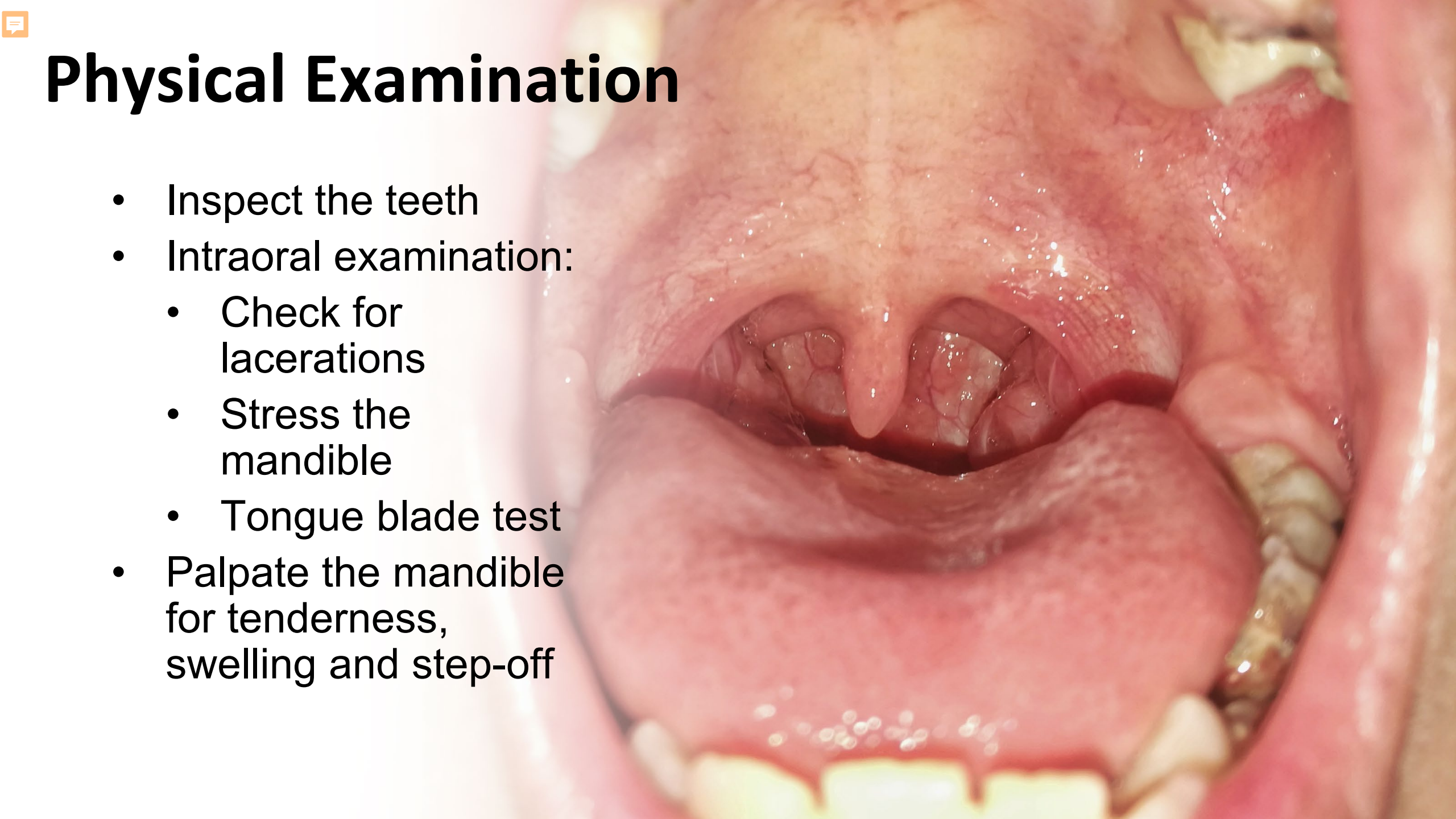

# Physical Examination

- Check visual acuity
- Check pupils for roundness and reactivity
- Examine the eyelids for lacerations
- Test extra ocular muscles
- Palpate around the entire orbits





# Physical Examination

- Examine the cornea for abrasions and lacerations.
- Examine the anterior chamber for blood or hyphema.

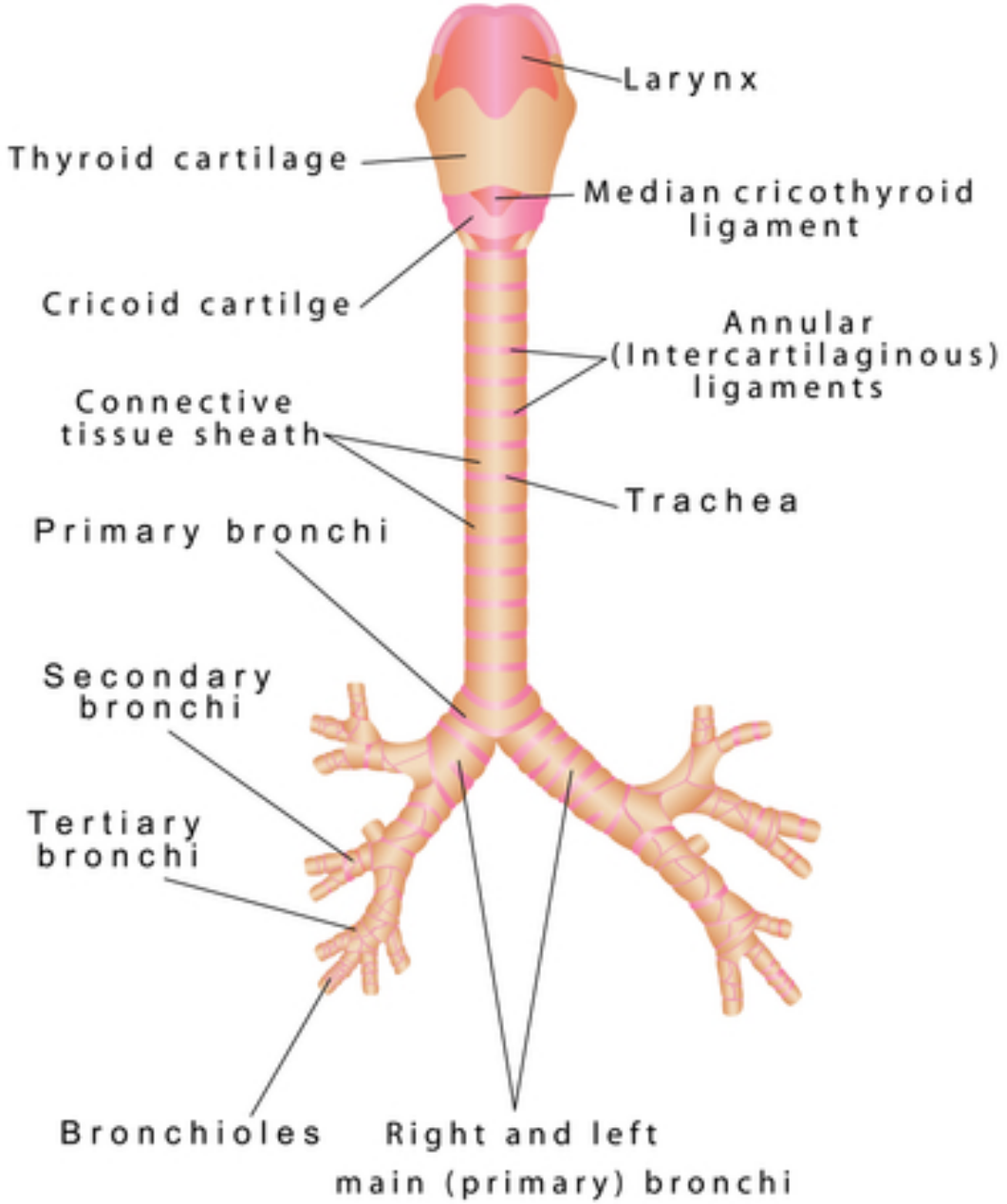


# Airway Management

- Protect and maintain airway
  - Pull tongue forward with padded forceps or sutures
  - Endotracheal intubation
  - Anticipate need for cricothyroidotomy
- Prevent aspiration
- Ensure adequate oxygenation and ventilation



# Airway Management

- Protection of airway
- Keep HOB elevated
- Aggressive pulmonary toilet
- Frequent suctioning

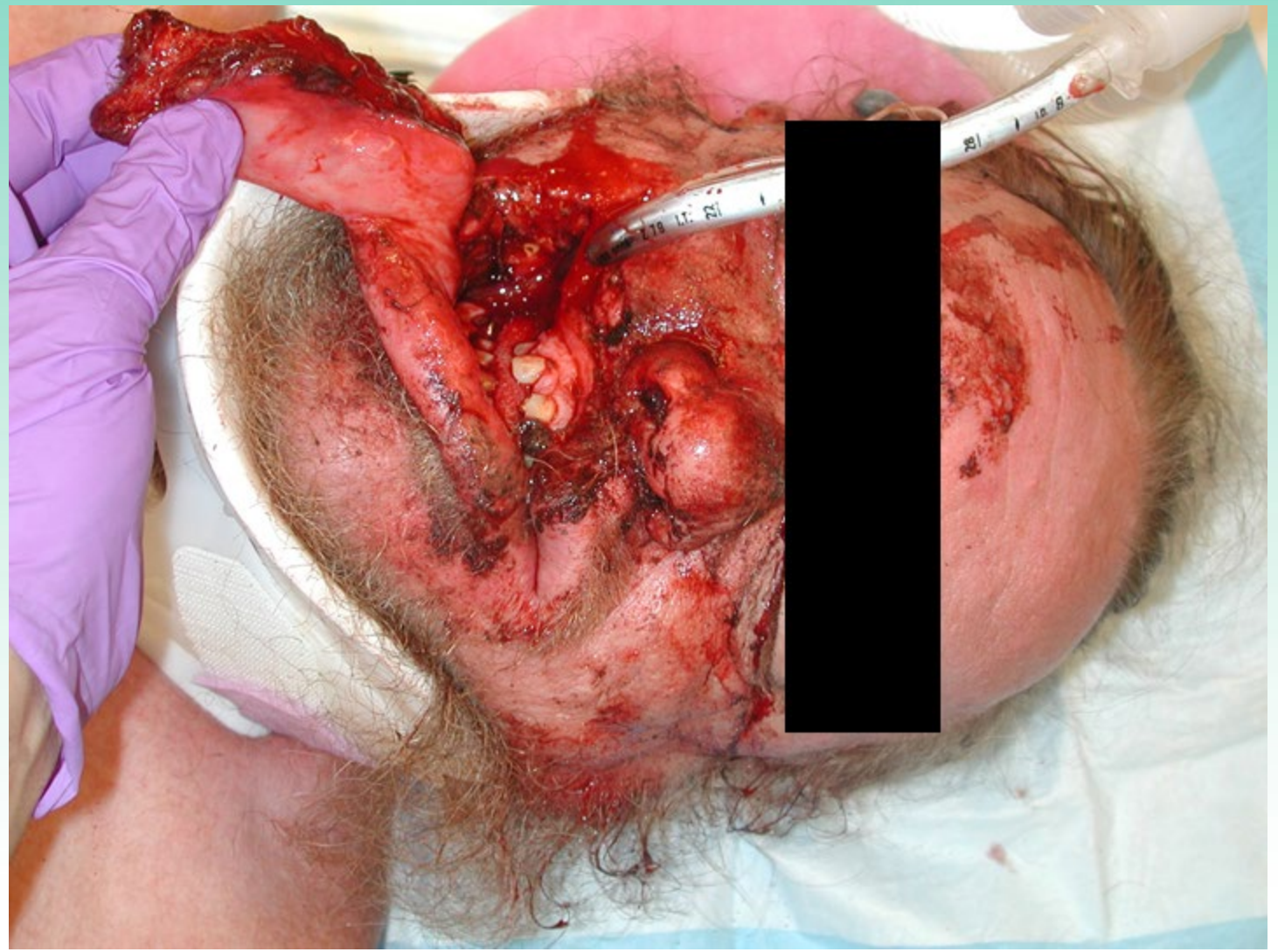



# Management

- Control hemorrhage
  - Direct pressure
  - Nasal and oral packing
  - Reduce fractures
- Restore intravascular volume
- Anticipate intracranial injury and need for intervention
  - Serial neurologic exams

# Management

**Nutrition Management**

- Early initiation of enteral feeding
- Keep HOB elevated
- Evaluate for swallowing dysfunction prior to oral feeding
- Wire cutters at bedside at all times

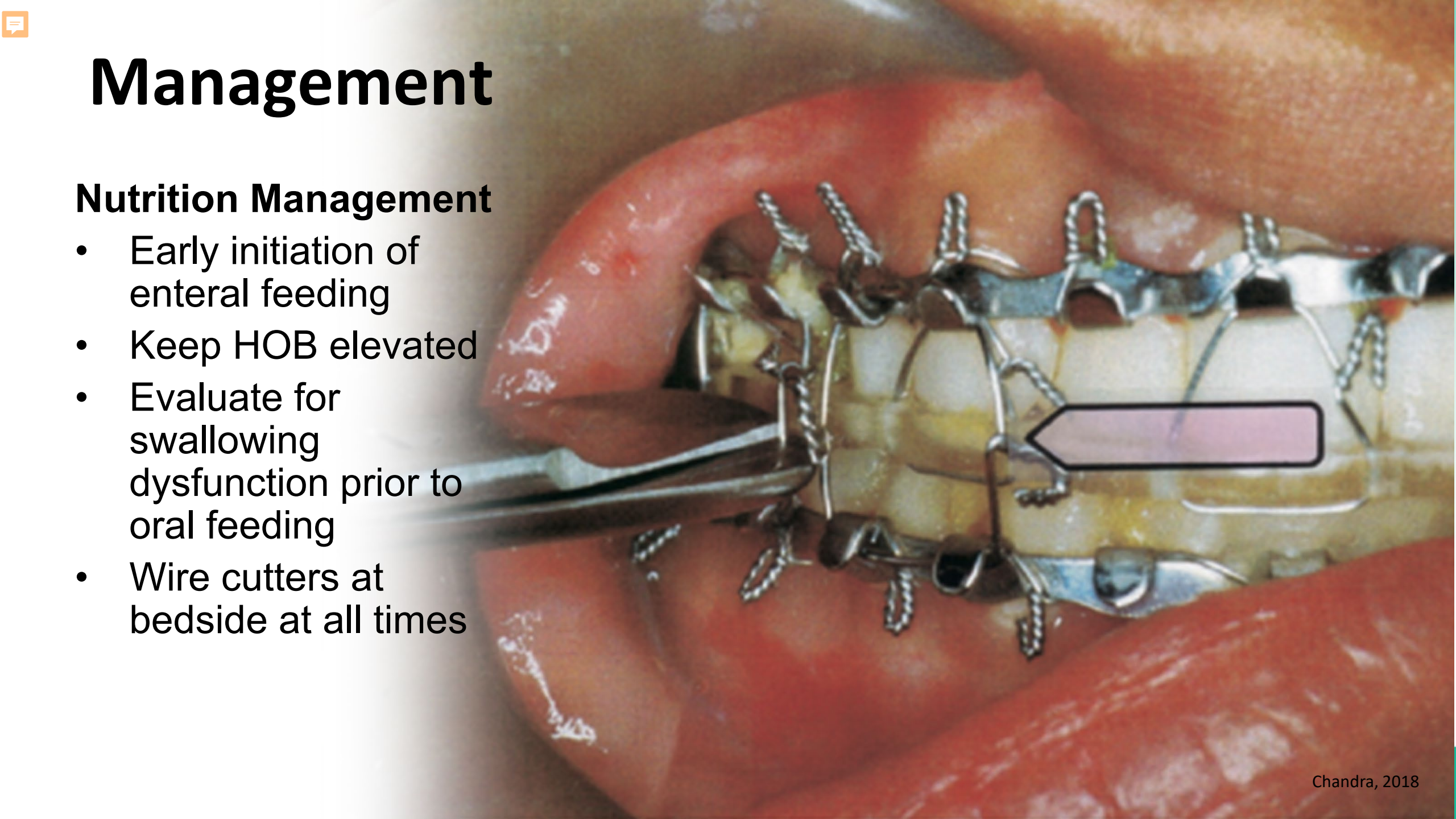

Chandra, 2018

# Management

Prevention of infection

- Perioperative antibiotics
- Frequent oral lavage
- Minimize nasal packing and tubes
- Decongestants
- Avoid blowing nose
- Avoid foreign bodies or instrumentation in nares or ear canal

# Management

- Protect eyes from further injury
- Pain management
- Early Rehab Consult

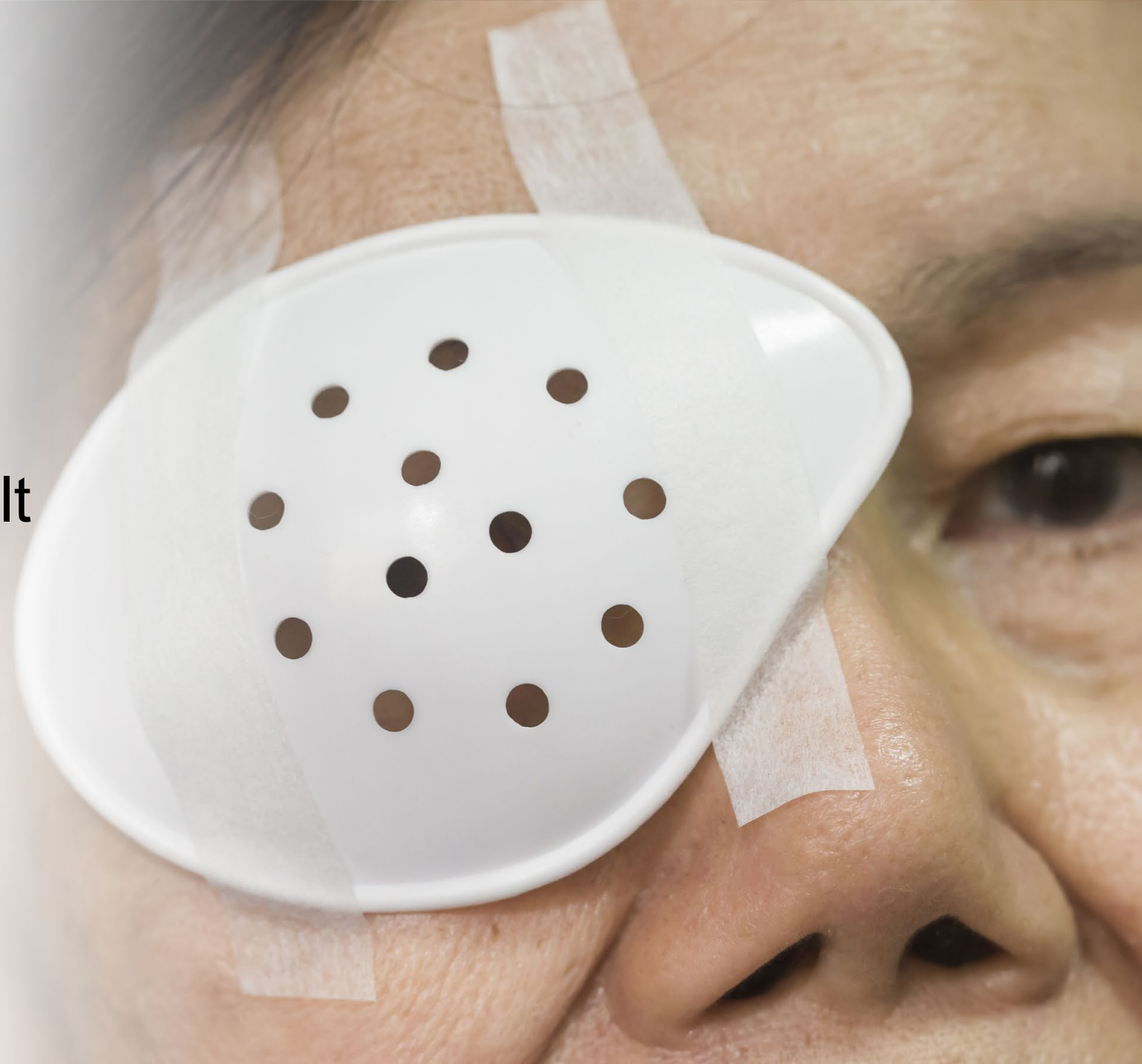

# Direct Eye Trauma

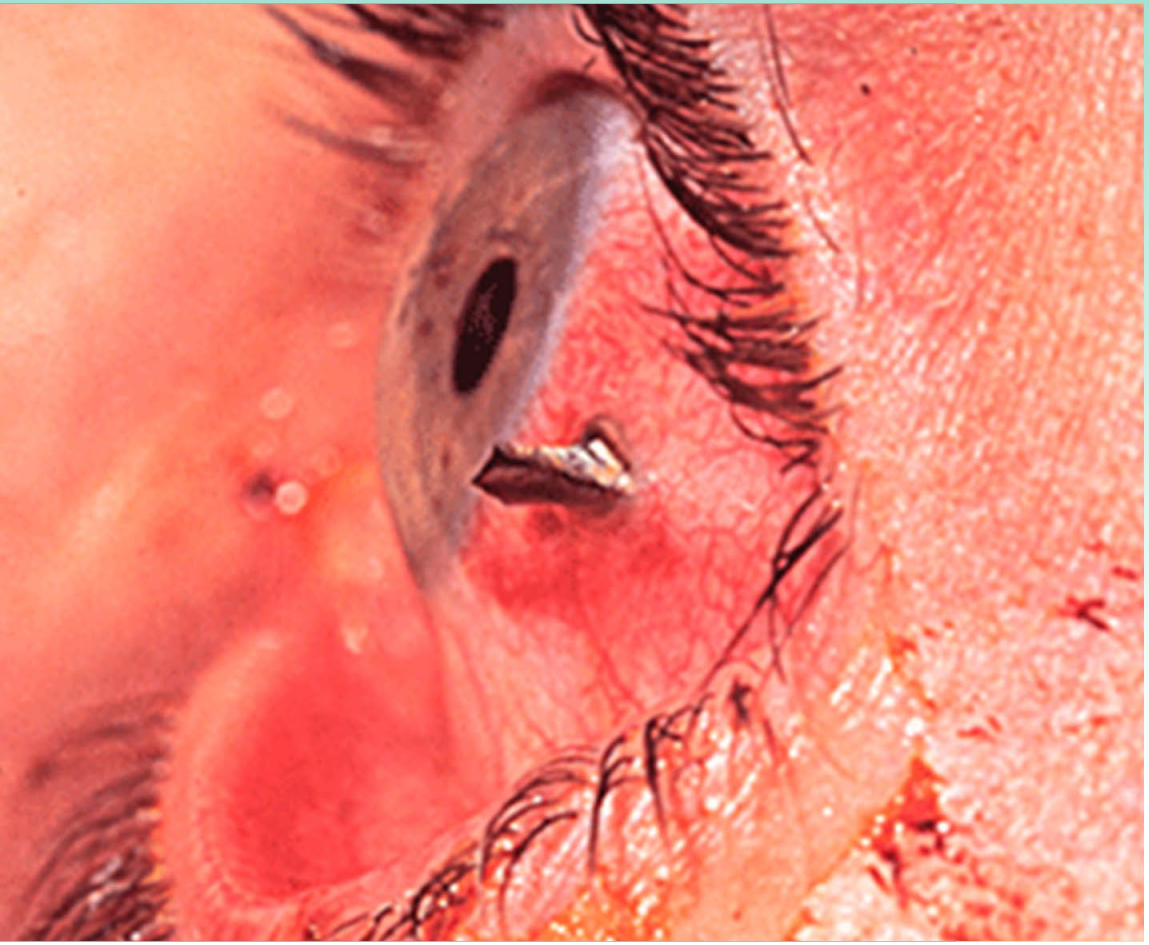

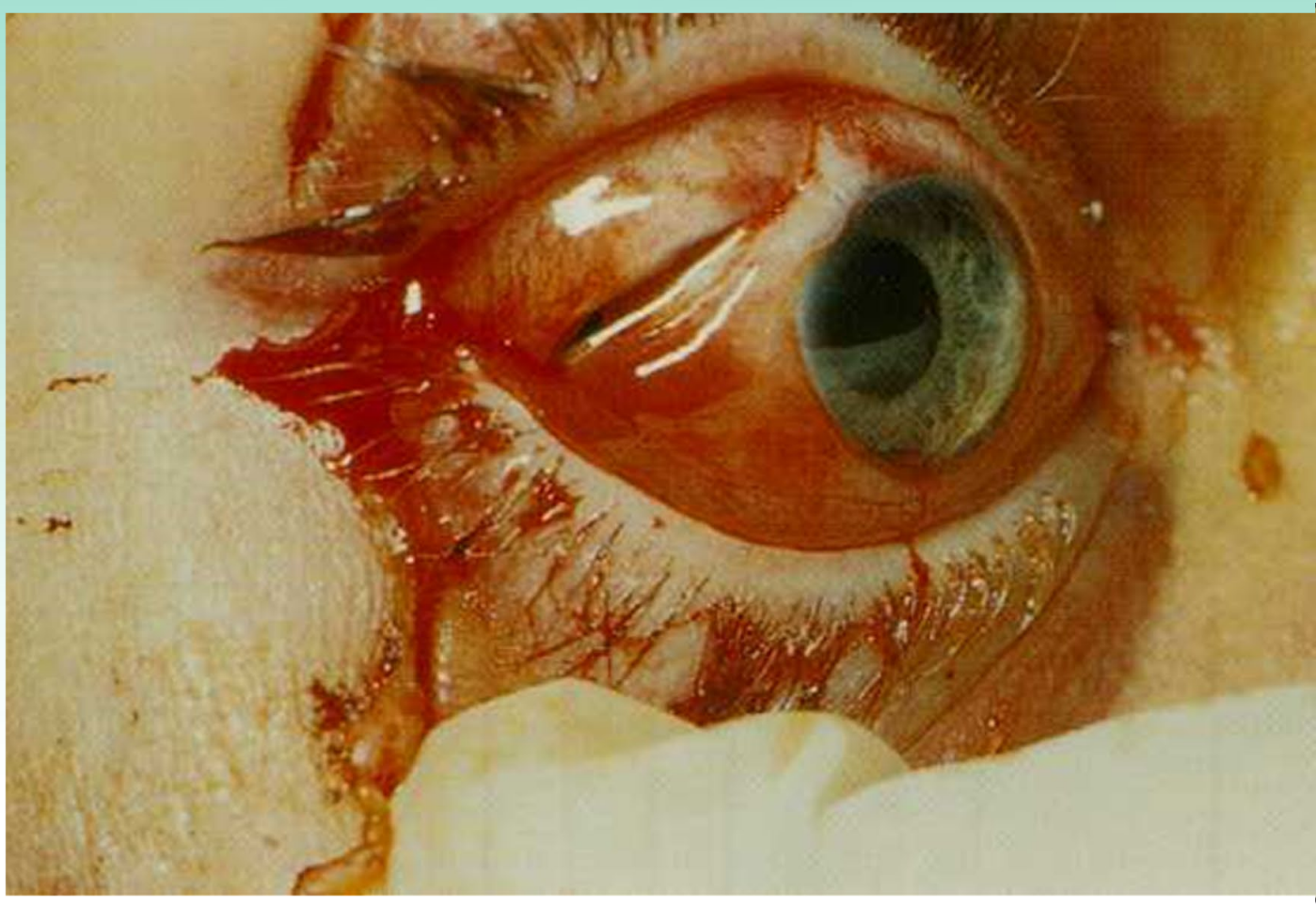

# Blast Injury: Thermal Injury





# Thermal Injury

- Eye is usually spared
- Corneal exposure may occur as burn heals and skin contracts



# Corneal Abrasion

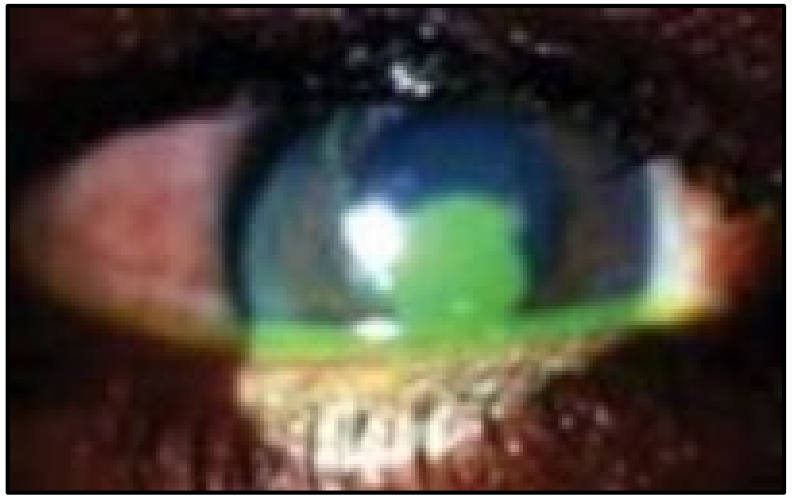



# Chemical Burns

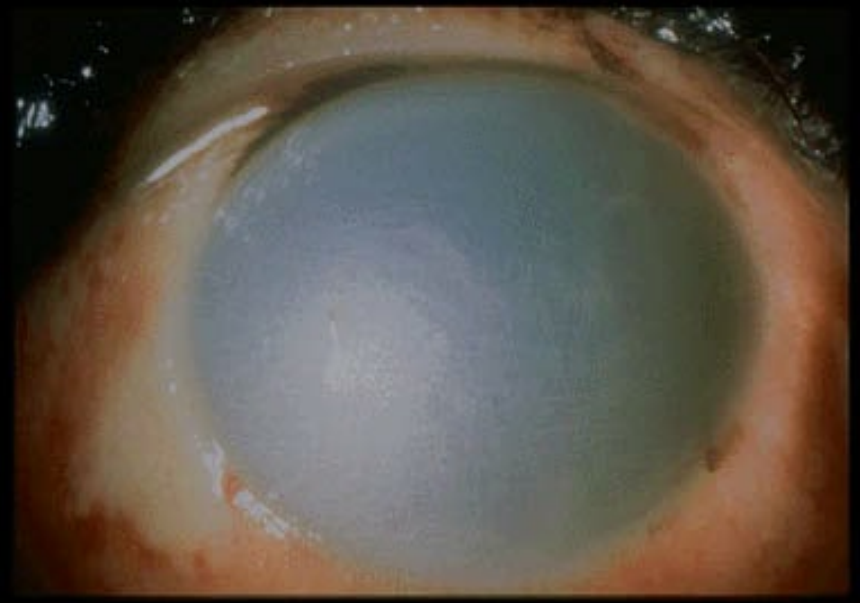



# Traumatic Hyphema

- Limit activity
- Keep HOB elevated
- Protect the eye
- Monitor intraocular pressure
- Cycloplegic agents
- Monitor for re-bleeding
- Avoid NSAIDS and anticoagulants
- Topical aminocaproic acid

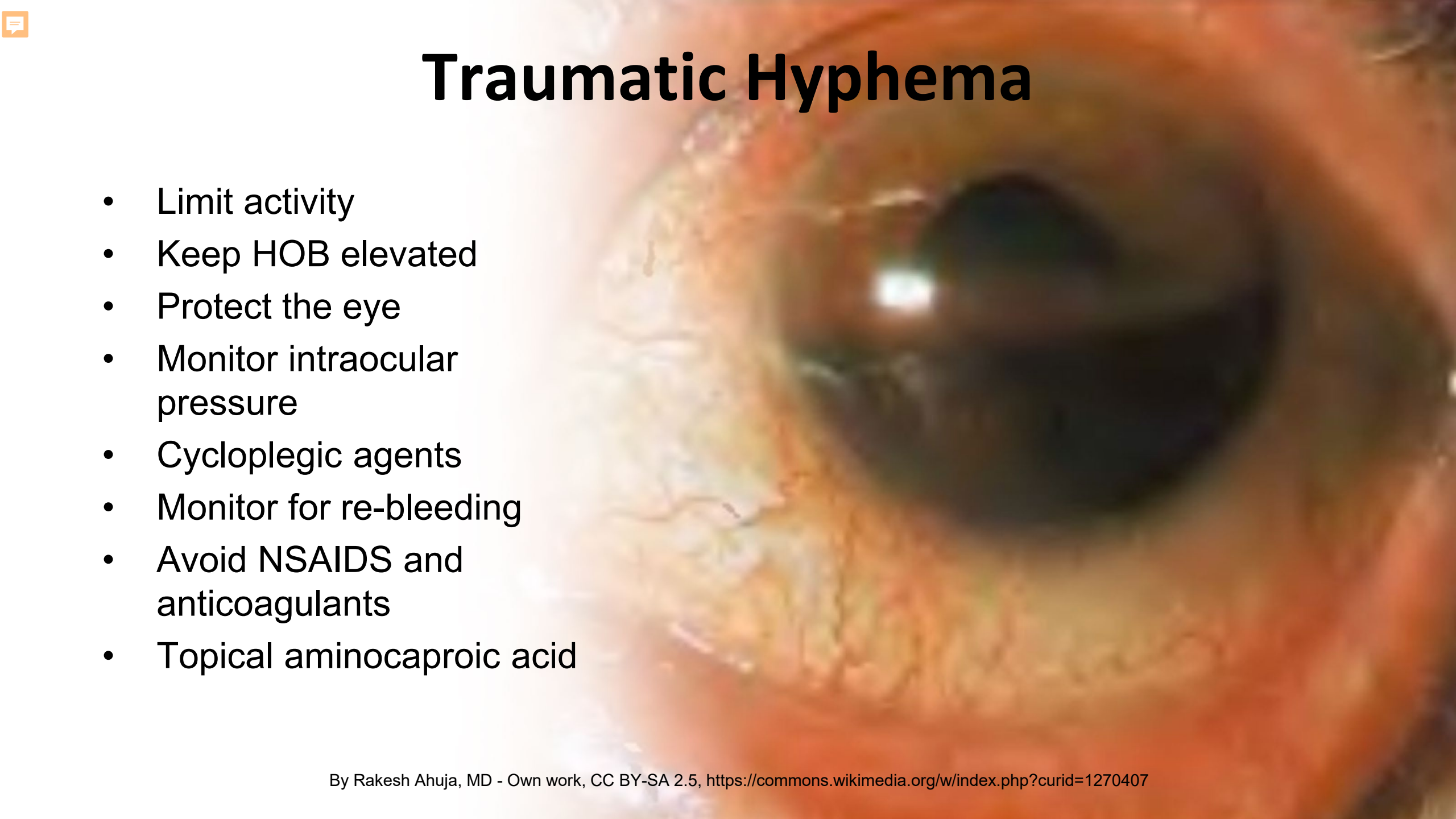

By Rakesh Ahuja, MD - Own work, CC BY-SA 2.5, https://commons.wikimedia.org/w/index.php?curid=1270407

# Lid Laceration

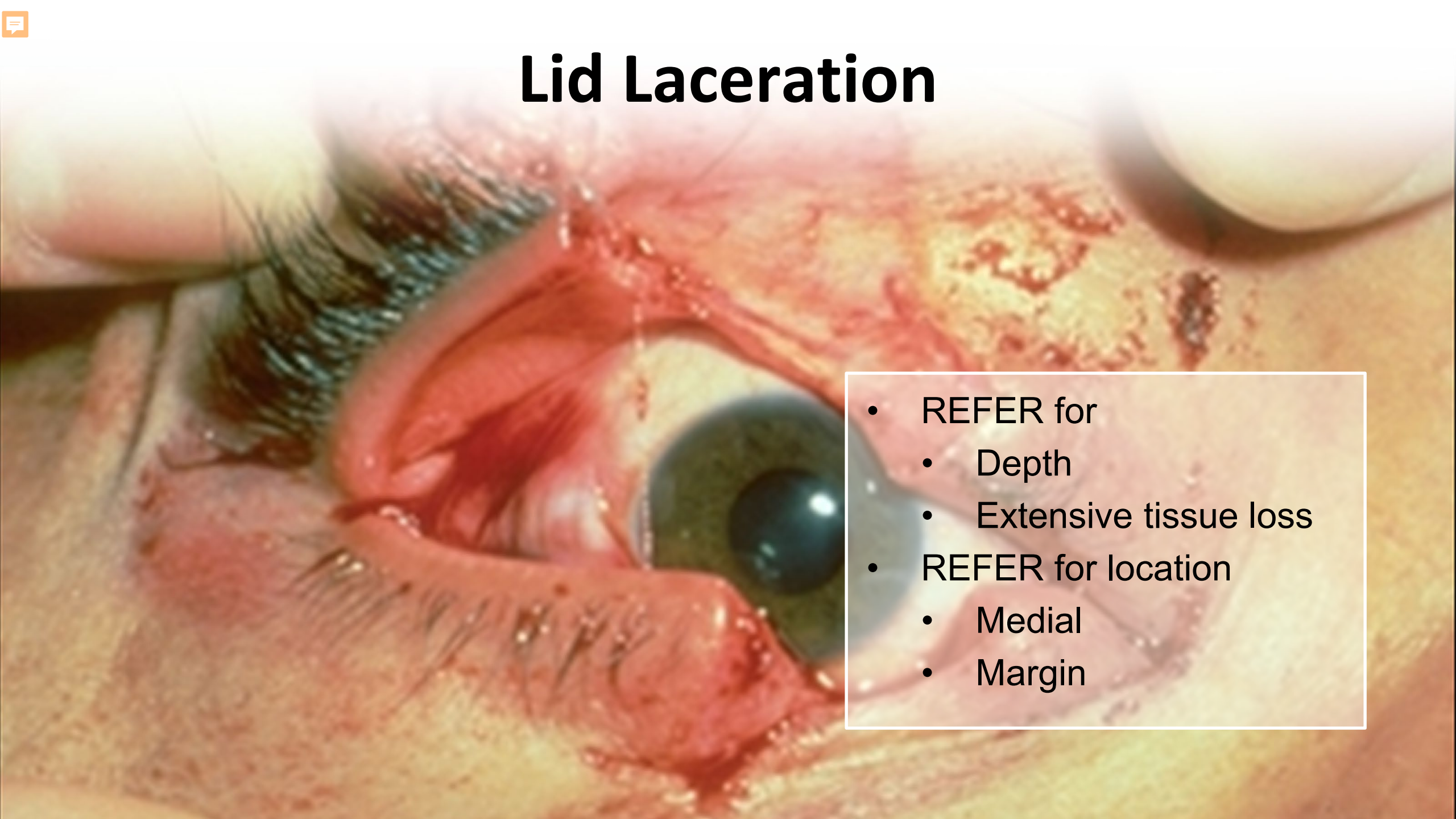

- REFER for
  - Depth
  - Extensive tissue loss
- REFER for location
  - Medial
  - Margin



# Ruptured Globe

- Penetrating
- Blunt
- Urgent opthomology consult
- NPO

Mosheni, 2022

# Open Globe

- Tetanus
- Antibiotics
- Minimize additional damage
- Avoid increasing intraocular pressure



# Sympathetic Ophthalmia

- Inflammatory condition
- Common after penetrating injury or ruptured globe
- Occurs 5 days to many years after injury
- Results in loss of vision of uninjured eye
- Prevented by early enucleation of injured eye

# Psychosocial Support

- Provide communication aids
- Frequent positive reinforcement
- Early referrals to psychiatric liaisons or counselors
- Early referrals to community agencies for the blind
- Referrals for home safety evaluations
- Referrals to local and state agencies for financial assistance

# Patient and Family Education

- Reinforce surgical plan of care
- Medications
- Nutrition management
- Wound care
- Tracheostomy care
- Avoid direct sunlight for 6-12 months
- Use of cosmetics

# Summary

- Facial and ocular trauma requires a comprehensive multidisciplinary team to maximize outcomes.
- Early incorporation of rehabilitation services is necessary for functional recovery.
- Overall prognosis of reconstruction may take months or years.